

anatomy hand-out

HUMAN BIOLOGY

(BASIS OF ANATOMY)

BY
DR. SAMEH DOSS (Ph.D)

PROFESSOR OF ANATOMY
FACULTY OF MEDICINE , CAIRO UNIVERSITY

رقم الايداع بدار الكتب

٢٠٠٠ / ١٧٦٥٤

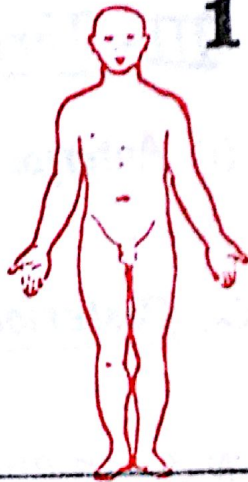
All Rights Reserved

DESCRIPTIVE ANATOMICAL TERMS

1

I- Anatomical positions

1) Erect anatomical position: for descriptive purposes, the human body (even a cadaver lying on a table) is regarded as standing erect, the eyes looking forwards, the upper limbs hanging by the sides with the palms facing forwards and the thumbs directed laterally (outwards). This position is used as a reference in describing the anatomy of the body.



2) Supine position: the body lies on its back.



3) Prone position: the body lies on its face.



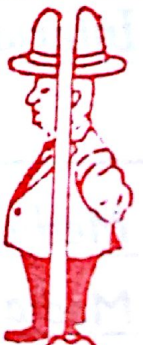4) Lateral decubitus position: the body lies on its side (right or left).



II- Anatomical planes & lines

1) The Coronal (Frontal) plane:

it is the plane which cuts the body vertically into an anterior part towards the front of the body and a posterior part towards the back of the body.



2) The horizontal plane:

it is a transverse plane which runs horizontally cutting the body into an upper (superior) and a lower (inferior) parts.



3) The median plane:

it is the vertical plane which passes in the middle line of the body dividing it longitudinally into right & left equal halves.



N.B: (a) anterior median line: is the line where the median plane meets the front of the body.

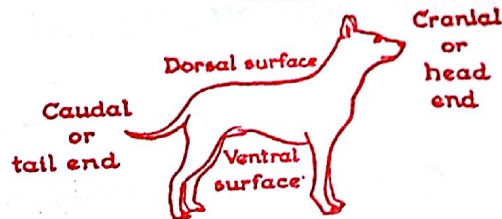
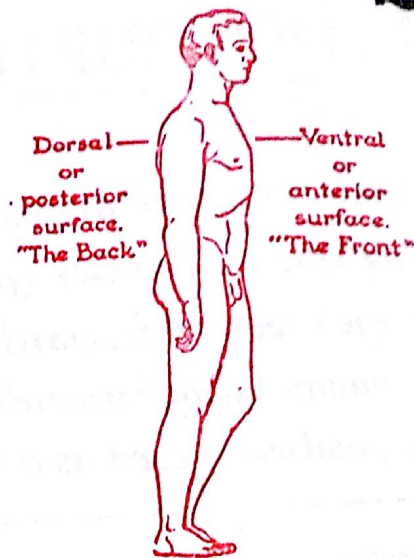
(b) posterior median line: is the line where the median plane meets the back of the body.

III - Terms of position:

(1) Anterior = in front of
= nearer to the front of the body

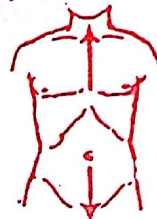
(2) Posterior = behind
= nearer to the back of the body

N.B: In animals, the term ventral replaces anterior & the term dorsal replaces posterior. However, the terms ventral & dorsal are still used in human anatomy



(3) Superior (upper or cranial or rostral)
= nearer to the upper end of the body.

superior or cranial



inferior or caudal

(4) Inferior (lower or caudal)
= nearer to the lower end of the body.

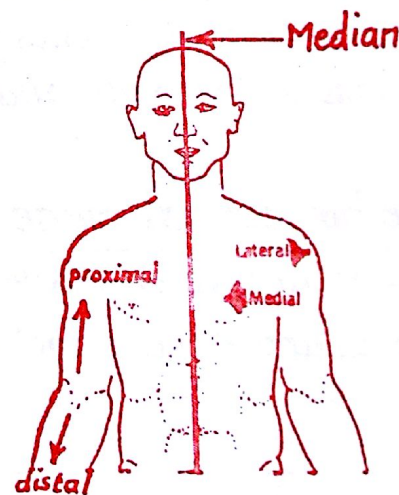
(5) Median = exactly in the middle line or median plane.

(6) Medial = nearer to the median plane.

(7) Lateral = away from the median plane.

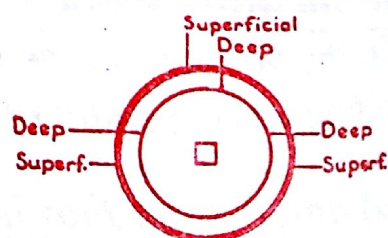
(8) proximal = nearer to the root of the limb.

(9) Distal = away from the root of the limb.



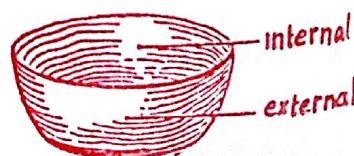(10) Superficial : towards the skin or the surface of the body

(11) Deep : further away from the skin or " " " "



(12) Internal (inner) = towards the cavity of a hollowed organ.

(13) External (outer) = towards the surface " " "



IV- Terms of movements

3

(1) Flexion (bending) : it is the movement which includes

- (a) approximation of 2 morphologically ventral surfaces
- (b) decreasing the angle between 2 parts of the body
- (c) assuming the foetal attitude (position of the foetus in the uterus)

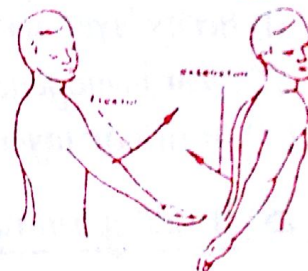
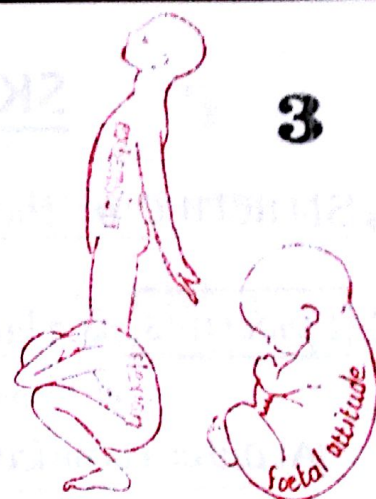(2) Extension (straightening) : the reverse of flexion & includes :

- (a) moving 2 ventral surfaces away from each other.
- (b) increasing the angle between 2 parts of the body.
- (c) assuming a position opposite the foetal attitude

N.B : there are some exceptions to these definitions of flexion & extension

(a) at the shoulder joint : Flexion moves the arm forwards & medially in front of the chest while extension moves the arm backwards

(b) Flexion of the thumb : is the medial movement of the thumb in front of the palm & parallel to its surface.



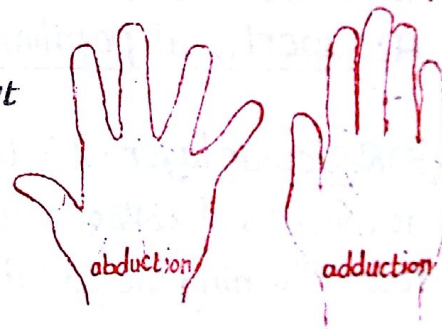
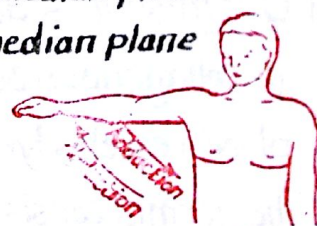(3) Abduction : is the movement which carries the limb away from the median plane.

(4) Adduction : " " " " " " " " towards the median plane

N.B : abduction & adduction of the fingers & toes are exceptions to the previous definitions where :

* abduction : is the movement of the fingers away from the long axis of the middle finger in the hand or the movement of the toes away from the long axis of the 2nd toe in the foot.

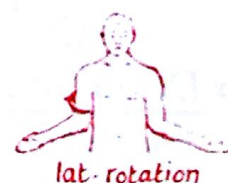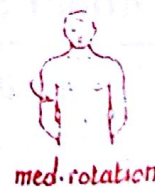* adduction : is the movement of the fingers or toes towards the above mentioned axes.



(5) Rotation : it is the movement where the limb rotates around its long axis. There are 2 types of rotation :

(a) medial rotation : rotation of the limb towards the middle line

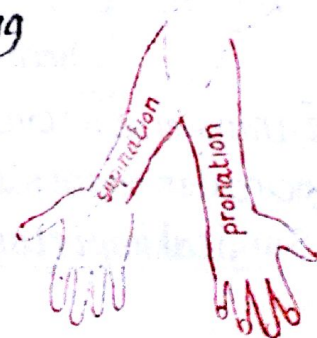(b) lateral rotation : " " " " away from " " "



(6) Supination and pronation : are rotatory movements occurring only in the forearm

(a) in supination : the radius lies parallel with the ulna and the palm of the hand faces forwards

(b) in pronation : the radius crosses in front of the ulna and the dorsum of the hand faces forwards



SKIN AND ITS APPENDAGES

4

* Structure of the skin: $\left\{ \begin{array}{l} (1) \text{ superficial epithelial layer called epidermis.} \\ (2) \text{ deep connective tissue layer called dermis.} \end{array} \right.$

I- Epidermis: is a layer of keratinized stratified squamous epithelium which is devoid of blood capillaries but contains free nerve endings. It is formed of 3 zones

(A) outer cornified zone formed of 3 layers:

- (1) horny layer formed of keratinized dead cells
- (2) Clear homogenous layer of packed dying cells
- (3) granular layer: flattened most superficial living cells

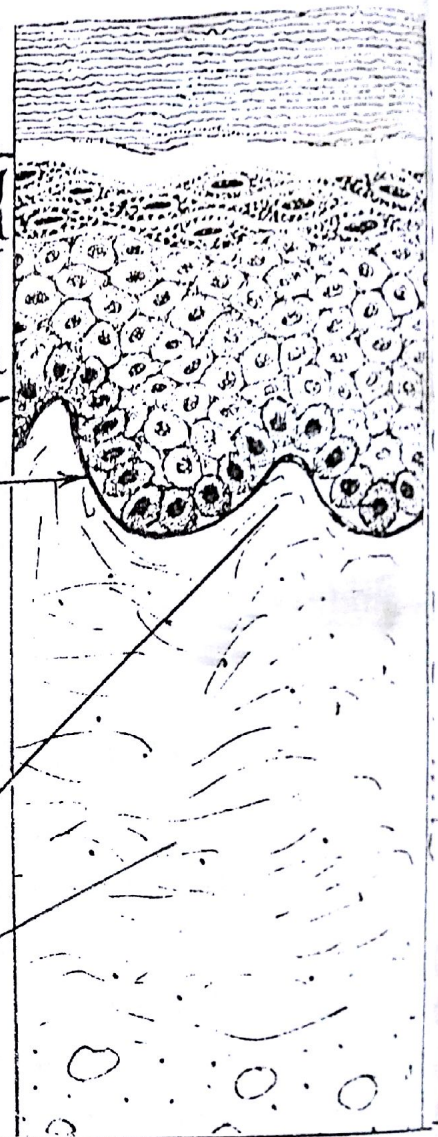(B) Inner germinative zone formed of 3 layers:

- (1) prickle cell layer: formed of many layers
- (2) basal " " : single layer of columnar cells
- (3) basement membrane: between the dermis & epidermis

II- Dermis: it is dense connective tissue proper rich in collagenous & some elastic fibres. It contains the blood vessels, lymphatics & nerves of the skin.

The dermis consists of 2 layers:

- (A) superficial papillary layer formed of conical papillae of loose connective tissue
- (B) Reticular layer: it is the dense deeper part of the dermis it consists of collagenous bundles arranged in parallel rows (forming the so called cleavage lines of the skin).



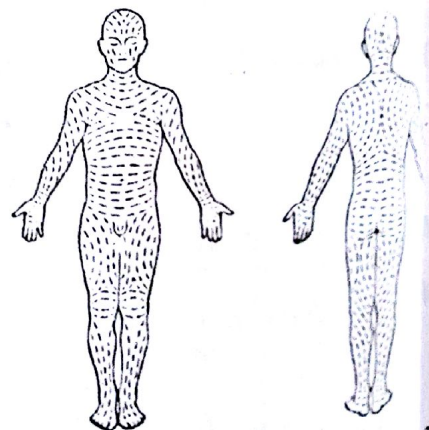
Langer's or Cleavage lines of the skin

* Definition: they are the lines along which the collagenous bundles of the dermis are mainly arranged.

* Distribution: they follow the following pattern:

- (1) longitudinal in the limbs except at the joints where they become parallel to the flexure lines around joints
- (2) transverse or circumferential in the neck, trunk & hands.
- (3) circular on the sides of the head & on the scapular regions.

* Surgical importance: surgical incisions should follow the cleavage lines to minimize cutting of the collagenous fibres which leads to bad scar.



Skin Creases

5

* Definition: they are small grooves or furrows due to folds of the dermis that are attached to deeper structures particularly deep fascia or subcutaneous bones.

* Types of skin creases:

(1) Tension lines: they are fine creases in the form of network of linear furrows which intersect each other at various angles dividing the surface of the skin into polygonal or lozenge shaped areas



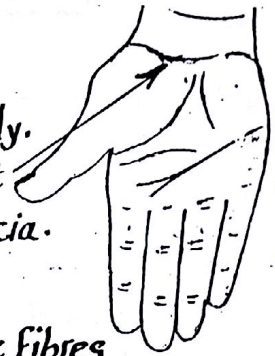(2) Papillary ridges (finger prints):

- they are elevations on the palmar surfaces of hands & feet, produced by elevations of the underlying dermal papillae.
- they are constant ridges that remain unchanged throughout life & are specific to the individual (used in medicolegal identification (التعرف على الأشخاص في الطب الشرعي)).
- they are divided into 4 patterns: (a) whorls (b) loops (c) arches (d) composite.



(3) Flexure lines:

- are deep skin grooves lying opposite the joints & movable parts of the body.
- they are marked on the palmar aspect of hand & fingers & on the front of the wrist
- they are produced by firm attachment of the skin to the underlying deep fascia.



(4) Relaxed tension lines (of Langer): see page 4

(5) Striae: if the skin is subjected to excessive tension, the elastic fibres will rupture producing radiating red lines e.g. striae gravidarum in the anterior abdominal wall of pregnant women. Later they will heal.

Colour of the skin

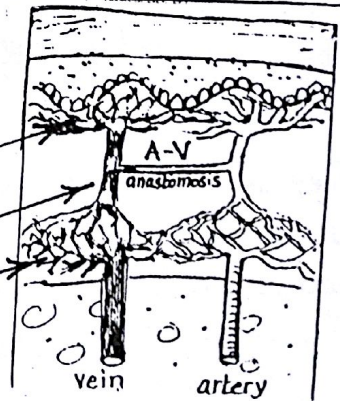
determined by the interaction of the following 3 pigments:

- (1) Carotene: the yellow or orange pigment found in the epidermal cells & the subcutaneous fat.
- (2) Melanin: dark brown pigment found in the melanocytes present at the dermo-epidermal junction
- (3) Haemoglobin: red pigment present in the R.B.Cs of the superficial cutaneous blood vessels.

Blood Supply of the skin

* The blood vessels supplying the skin are distributed as follows:

- (1) superficial plexus: in the superficial part of the dermis.
- (2) arteriovenous anastomosis: in the middle part of the dermis.
- (3) deep plexus: at the junction between the dermis & S.fascia



Nerve Supply of the skin

- The skin is richly supplied by sensory & autonomic fibres that form plexuses around the hair follicles & in the papillary layer of the dermis. Fine nerve endings also penetrate the deep layers of the epidermis.

FUNCTIONS OF THE SKIN

(1) Protection: it protects the underlying soft tissues because its horny layer is impermeable & resistant to mechanical, osmotic, chemical & thermal damage. It also acts as a barrier against invasive micro-organisms

(2) Heat regulation: (a) in cold weather, it prevents excessive heat loss by vasoconstriction of its blood vessels
(b) in hot weather, it assists heat loss by sweating & vasodilatation of its blood vessels.

(3) Sensory organ: the skin contains sensory end organs concerned with pain, temperature, touch & pressure bringing informations about external environment

(4) Excretion: skin has a little excretory function for salts & urea with the sweat.

(5) Metabolic: skin is capable of converting 7-dehydrocholesterol into vitamin D by the action of the ultraviolet rays.

APPENDAGES OF THE SKIN

1- Hair


* Distribution: (a) most abundant in the scalp, axilla & pubic region
(b) absent in the palm & sole

* Structure of hair: it is formed of 2 parts: root & shaft.

(a) shaft: is the part projecting from the surface of the skin

(b) root: is the part embedded in the skin

- the root + the surrounding tissue is called hair follicle.



* Types of Hairs:

(a) primary (lanugo hair): it is the first hair to appear & covers the whole skin of the fetus

(b) permanent skin: it is the hair found in the adult.

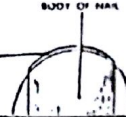
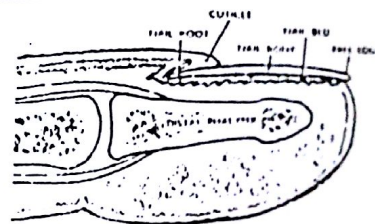
2- Nails

A nail is a flattened horny plate having a root & a body:

* The root: is the part embedded in the skin (not exposed)

* The body: is the exposed part of the nail having:

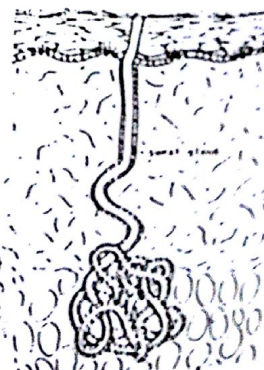
* The free distal border



3- Sweat Glands

They are found in every part of skin but are numerous in palm & sole. each gland is a single tube whose deep part is coiled & lies in the deep part of the dermis (or even in the superficial fascia).

They are innervated by sympathetic nerve fibres.



4- Sebaceous glands

* are most abundant in the scalp & face and absent in the palm & sole.

* are usually related to the hair follicles on one side & erector pili muscles on the other side.

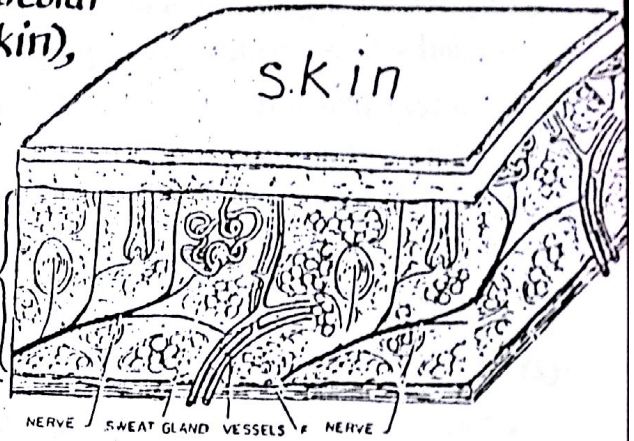
* their ducts usually open in the hair follicles but may open directly on the skin.

* its secretion is called sebum which is fatty, lubricant & antibacterial.

* Definition : it is a membrane-like sheets of fibro-areolar connective tissue that covers the body (under the skin), surrounds muscles & binds tissues & organs together.

* Types : according to site & structure, fascia includes:

- (1) superficial fascia
- (2) Deep fascia
- (3) internal fascia



1- SUPERFICIAL FASCIA

* Site : it lies deep to the skin, connecting its dermis to the underlying deep fascia.

* Structure : mixture of loose areolar and adipose connective tissue.

* Characteristics:

(1) it is thick & rich in fat in the following sites:

- (1) the breast
- (2) anterior abdominal wall
- (3) buttock

(2) it is thin & devoid of fat " " " "

- (1) eye lids
- (2) the penis
- (3) the scrotum

(3) it is exceptionally dense in the scalp, palm of the hand & sole of the foot.

Functions of the superficial fascia:

- (1) being rich in fat, it acts as an insulator for conservation of body temperature.
- (2) it gives the surface of the body a rounded contour by filling up the hollows & masking the irregularities at the surface of the body.
- (3) it facilitates the movement of the skin over the underlying structures.
- (4) it serves as a medium through which cutaneous vessels & nerves pass to the skin.
- (5) it contains deeply situated sweat glands, the mammary gland.
- (6) in certain sites of the body e.g face, neck & scrotum, the superficial fascia contains sheets of superficial muscles (these muscles are called panniculus carnosus).
- (7) it acts as a reservoir of fat.

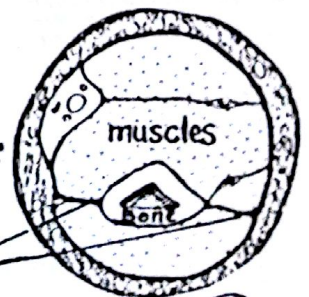


2- DEEP FASCIA

* Structure : non-elastic tough fibrous tissue sheet rich in collagenous fibres

* Sites : it lies undercover of superficial fascia forming strong membranes which:

- (1) envelop muscles forming sheaths around them.
- (2) separate different groups of muscles forming intermuscular septa
- (3) form thick bands across tendons retaining them in position (retinacula)
- (4) enclose big neurovascular bundles forming sheaths around them.

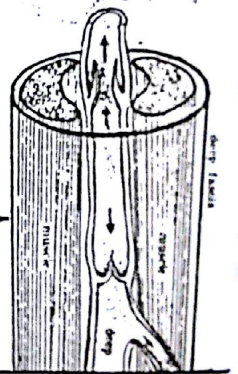
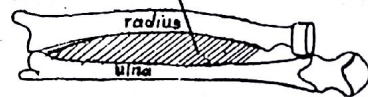
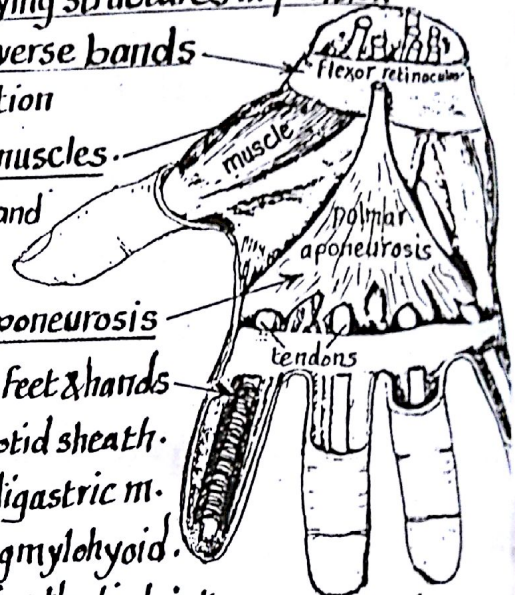


* Characters of deep fascia:

- (1) it passes freely over muscles but is firmly attached to bones and ligaments
- (2) in limbs & over nonexpansile parts of the body it forms tough well defined membranes
- (3) it is very thin or absent over expansile parts of the body (face, thorax & abdomen).
- (4) it is exceptionally dense in certain places as palm of the hand & sole of the foot.

* Functions of Deep fascia:

- (1) it preserves the surface contour of the limbs & keeps the underlying structures in position
- (2) it is thickened around joints e.g. wrist & ankle to form transverse bands called retinacula which retain the underlying tendons in position
- (3) in certain sites the deep fascia gives extra origin to some muscles
- (4) in areas subjected to pressure or friction as the palm of hand or sole of the foot, the deep fascia is extremely thickened forming a mechanically protective layer e.g. plantar & palmar aponeurosis
- (5) it forms fibrous sheaths around the flexor digital tendons of feet & hands
- (6) it forms sheaths around big vessels e.g. femoral sheath & carotid sheath.
- (7) it forms fibrous pulleys for tendons of certain muscles e.g. digastric m.
- (8) " " median raphe where 2 muscles of both sides insert e.g. mylohyoid.
- (9) it sends intermuscular septa which extend deeply dividing the limb into compartments containing separate muscle groups
- (10) a sheet of deep fascia may extend between 2 bones interosseous membrane which connects bones & gives origin to muscles



(11) Circulatory function:

the deep fascia promotes the circulation in the deep veins and lymphatics vessels in association with muscular activity. This can be explained by the fact that when muscles contract inside tight fascial sheath they compress veins & lymphatics thus propelling the venous blood & lymph upwards towards the heart against gravity.

III- Internal Fascia

* Definition: it is the C.T. which lines the body cavities from inside or extends between different organs

* Characters & Functions:

- (1) it forms tubular sheaths around vessels & nerves e.g. femoral sheath around femoral vessels
- (2) it lines the cavities of the body e.g. diaphragmatic fascia & pelvic fascia.
- (3) it forms strong fibrous coats for important organs e.g. fibrous pericardium around the heart.
- (4) it forms supporting ligaments for certain organs e.g. pelvic organs
- (5) it fixes the internal organs in position & fills the gaps between them

N.B: the internal fascia combines the features of the superficial & deep fascia being loose and areolar in certain parts & dense and fibrous in other parts of the body.

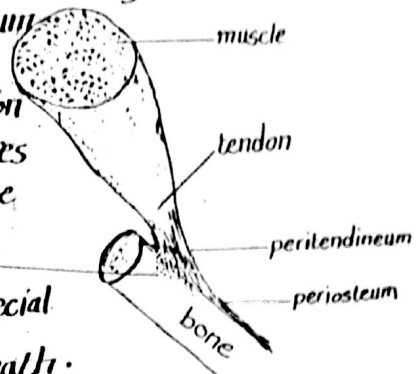
TENDONS

* Definition: a tendon is a tough, cord like tissue that attaches a skeletal muscle to other structure (usually bone but occasionally to the dermis of the skin).

* Structure: the tendon is formed of longitudinally arranged bundles of collagenous fibres surrounded by C.T. sheath called peritendineum (the continuation of the perimysium of the muscle).

* Attachment: on reaching a bone the peritendineum of the tendon blends with the periosteum while the collagen fibres penetrate through the cortex of the bone forming the perforating fibres of Sharpey.

* Protection: the tendons are protected against friction by special lubrication offered by a bursa or a synovial sheath.



BURSAE

* Definition: a bursa is a closed flattened sac of synovial membrane filled with synovial fluid. It has the shape & size of a coin.

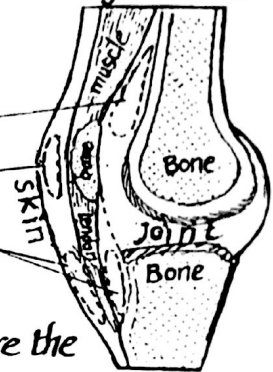
* Sites: bursae occur in close relation to joints & may communicate with the joint cavity.

* Function: they diminish friction between rubbing surfaces

* Types: according to their sites, bursae are classified into:

- (1) submuscular: present between a muscle & a bone
- (2) subcutaneous: " " the skin & bone
- (3) subtendinous: " " a tendon & an underlying structure
- (4) interligamentous: " " 2 tendons.

(5) adventitious bursa: newly formed bursa occurring at sites where the skin is subjected to repeated pressure against bone to provide free skin mobility.



SYNOVIAL SHEATHS OF TENDONS

* Definition: a synovial sheath is a tubular bursa that envelops a tendon

* Sites: it occurs in places where a tendon is subjected to friction or pressure on two or more surfaces (front & back) as in the following sites:

- (1) where tendons pass under fibrous retinacula
- (2) where " " through osteofibrous canals
- (3) " " " " bony grooves

* Function of the synovial sheath:

it prevents friction between the tendon and the surrounding structures thus protecting the tendon from injury & facilitates its movement.

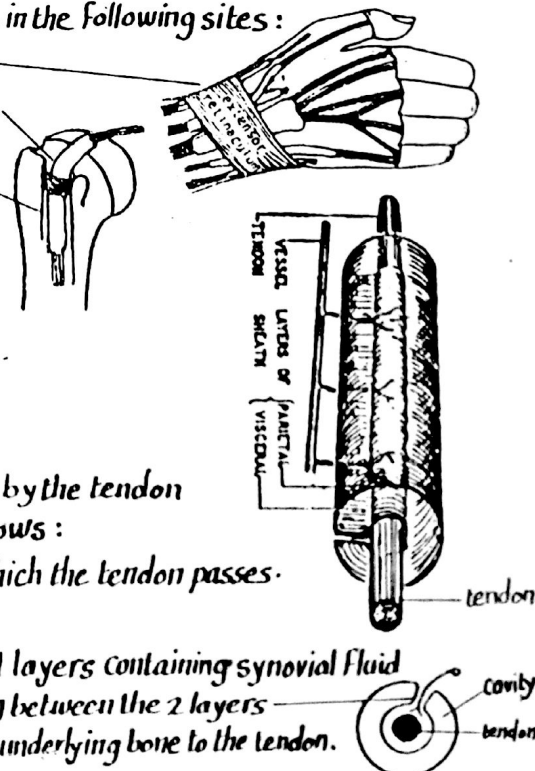
* Structure of the synovial sheath:

the synovial sheath is a tubular bursa invaginated by the tendon & thus it is formed of 2 layers & a cavity as follows:

- (1) parietal (outer) layer lining the canal through which the tendon passes.
- (2) visceral (inner) layer enveloping the tendon

(3) potential cavity between the parietal & visceral layers containing synovial fluid

(4) Vincula (mesotendon): a synovial fold extending between the 2 layers of the sheath & transmitting blood vessels from the underlying bone to the tendon.



CARTILAGE

10

* Definition: It is a form of supporting tissue which combines a certain amount of rigidity with considerable flexibility and elasticity.

* properties of Cartilage:

- (1) It is tough and resilient (unlike bone which is hard & non-resilient).
- (2) it is devoid of nerves, blood vessels & lymphatics (unlike bone which is highly vascular).
- (3) it resists friction, pressure & compressive forces (therefore it covers the articular surface).

* Structure:

- (1) Cartilage cells: called chondroblasts & chondrocytes
- (2) Matrix: in which C.T fibres are embedded.
- (3) perichondrium: a covering fibrous sheath capable of cartilage formation.

* Types of cartilage: according to the nature of the C.T fibres present in the matrix, cartilage can be classified into 3 types:

- Hyaline cartilage
- Fibro cartilage
- Elastic cartilage

1- HYALINE CARTILAGE

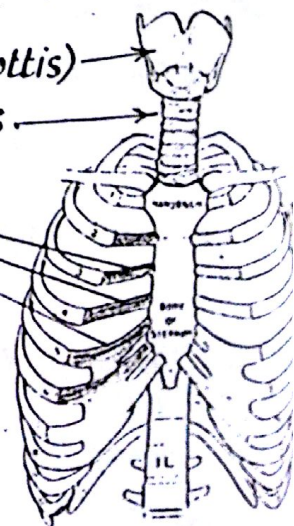
* Structure: the matrix contains very scanty fine collagenous fibres which cannot be seen by the naked eye. This gives the hyaline cartilage a glossy translucent appearance.



* Sites (distribution) of hyaline cartilage in the body:

- (A) During embryonic life (temporary): it forms models of all bones of the skeleton (except the clavicle & certain skull bones, providing the basis of ossification).
- (B) In the adult life (permanent): it is distributed as follows:

- (1) Respiratory cartilages
 - laryngeal cartilages (except epiglottis)
 - tracheal & bronchial cartilages
- (2) Thoracic wall cartilages (Costal cartilages).
- (3) articular cartilages covering bony ends




* Ability to regenerate: being avascular, hyaline cartilage is incapable of regeneration after injury.

* Effects of aging: some hyaline cartilages have a tendency to ossify in old age e.g. laryngeal cartilages.

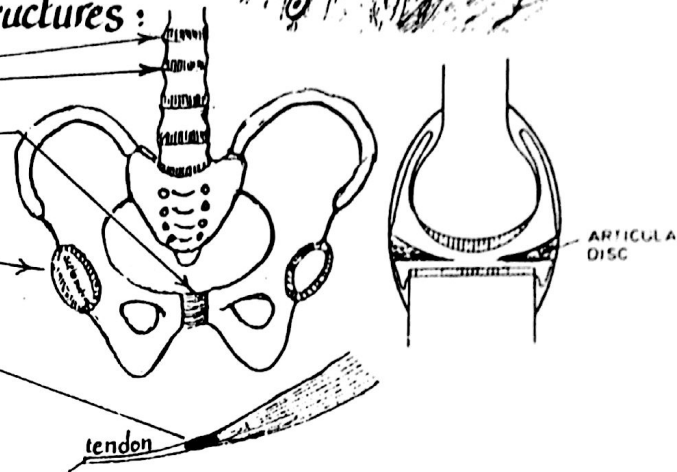
2- FIBROCARILAGE

* Structure : in this type, the matrix is rich in collagenous bundles with small scattered groups of cartilage cells. This type is tough and has great tensile strength.



* Sites : fibrocartilage is present in the following structures :

- (1) intervertebral discs
- (2) symphysis pubis
- (3) labrum glenoidale of the shoulder joint & labrum acetabulare of the hip joint.
- (4) articular discs inside some synovial joints.
- (5) sesamoid structures inside certain tendons.

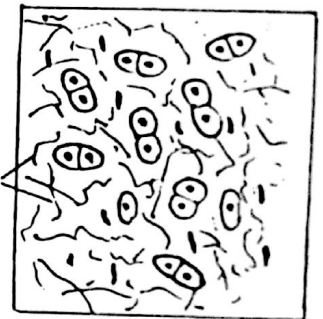


* Ability to regenerate : If damaged, Fibrocartilage can repair itself slowly.

* Effect of aging : it does not show any tendency to ossify in old age.

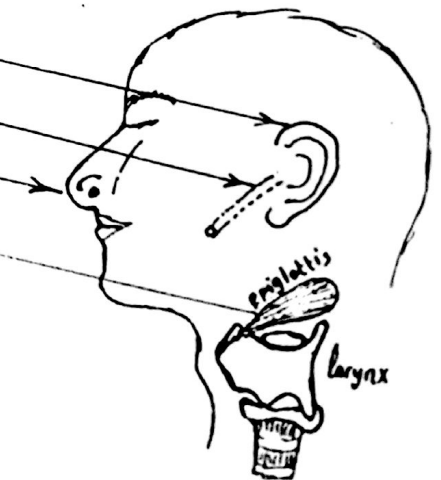
3- YELLOW ELASTIC CARTILAGE

* Structure : in this type, the matrix is rich in network of elastic fibres which gives the cartilage a yellow colour & marked resilience (elasticity). It has no perichondrium.



- * Sites :
- (1) cartilage of the auricle of the ear
 - (2) " " " Eustachian tube
 - (3) " " " tip of the nose
 - (4) Epiglottis of the larynx

* Effect of aging : it is never replaced by bone in old age.



* It is the hardest form of connective tissue.

* Properties of bone: bone is a living tissue characterized by:

- (1) its rigidity & high Calcium Content
- (2) its vascularity: it is richly supplied with blood vessels & nerves.
However it is devoid of lymphatics.
- (3) it has a great reparative power (regeneration after fracture or disease)

* Structure: bone is formed of 2 main components:

- (1) Organic framework (30%) formed of bone cells & collagen fibres. It gives the bone resilience & resistance to tensile forces.
- (2) Inorganic salts (70%) mainly calcium carbonate & phosphate. It gives the bone its hardness & resistance to compression forces.

* Functions of bone:

- (1) it forms the skeleton which provides a supporting framework to the body.
- (2) it transmits the body weight to the ground.
- (3) it affords protection to the vital structures of the body e.g:
 - (a) the skull protects the brain
 - (b) the vertebral column protects the spinal cord
 - (c) the thoracic cage protects the heart & lungs.
- (4) bones give attachment to muscles & act as levers for locomotion.
- (5) bone acts as storehouse for calcium & phosphorus.
- (6) bone marrow acts as the factory in which blood cells are formed.

THE SKELETON

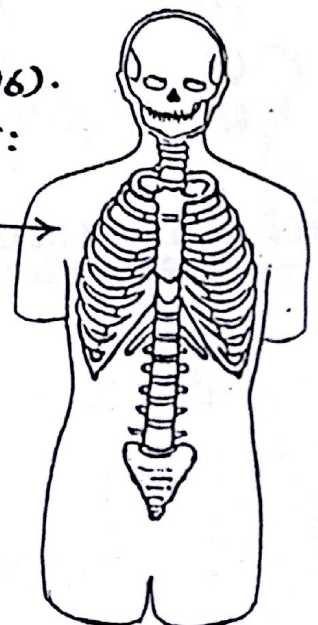
* the skeleton consists of all bones of the body (206).

* It is divided into 2 main parts: axial & appendicular:

(A) Axial Skeleton (80 bones):

it is the skeleton of the head & trunk & includes:

- (1) the skull, ear ossicles (3) & the hyoid bone.
- (2) the ribs & sternum.
- (3) the vertebral column.



(B) Appendicular Skeleton (126 bones):

- it is the skeleton of the extremities & include :

(1) bones of the upper limbs (64 bones)

(2) bones of the lower limbs (62 bones)

* Classification of bones :

bones can be classified according to the following items :

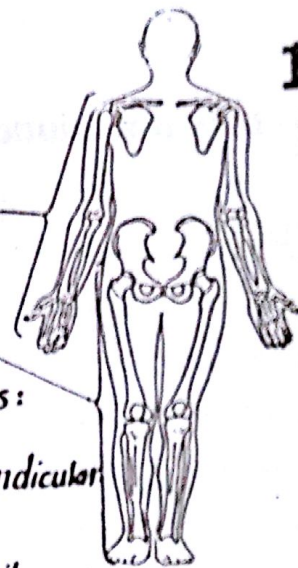
(1) according to their position in the skeleton : axial & appendicular

(2) according to their structure : Compact & Cancellous.

(3) according to their development (ossification) : intracartilagenous & intramembranous.

(4) according to their shapes :

(a) long (b) short (c) flat (d) irregular (e) pneumatic (f) sesamoid.



Structural Classification

* According to structure, bones are classified into 2 types { Compact bone
Cancellous "

Morphological Classification of bones

1-Long bones

* Site : they are found mainly in the upper & lower limbs.

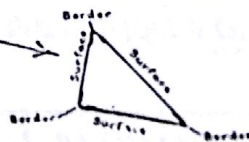
* parts : each long bone is formed of a shaft & 2 ends

(A) the shaft (diaphysis)

- is tubular in shape & has a central canal called medullary cavity filled with yellow bone marrow.

- it is formed of dense compact bone (thick in the middle but becomes thinner towards the ends).

- the typical long bone has 3 surfaces & 3 borders i.e triangular in cross-section.

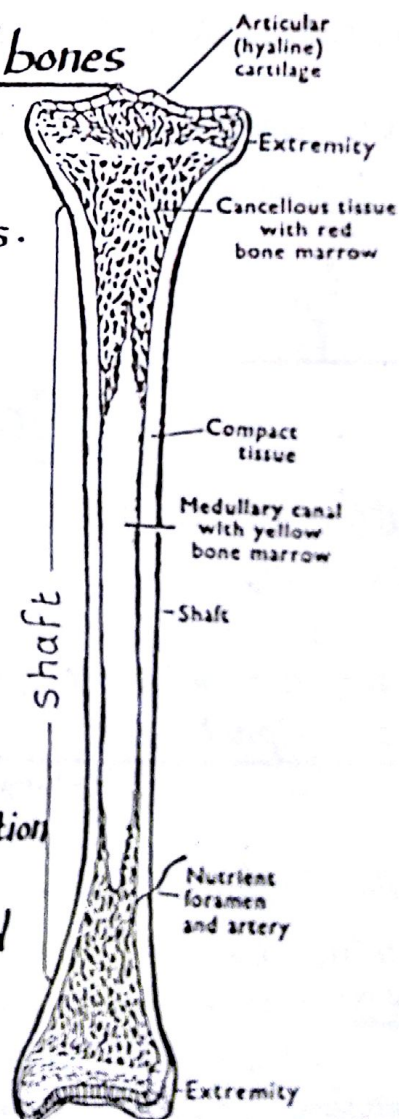


(B) the ends (epiphyses) :

- they are expanded for the purposes of articulation & muscular attachments.

- they are constructed of cancellous bone covered with thin layer of compact bone.

- the articular surface of each end is covered with a hyaline articular cartilage



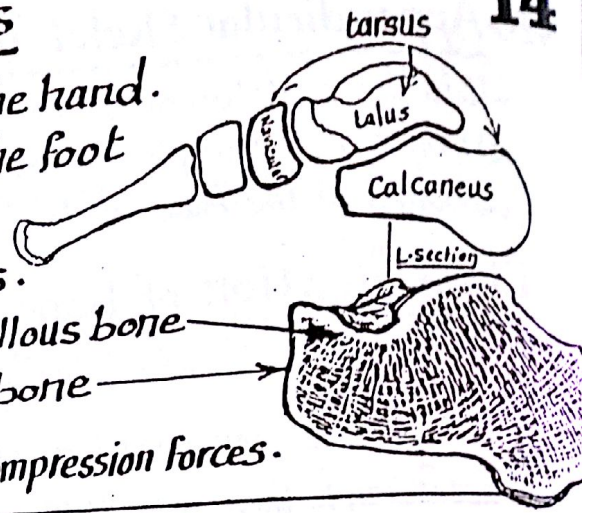
2- Short bones

* Sites: they are found in : (a) Carpus of the hand.
(b) tarsus of the foot

* Characters :

- (a) they are small in size having no shafts.
- (b) each short bone is constructed of cancellous bone with a thin covering shell of compact bone

* Function : they limit movements and resist compression forces.



3- Flat bones

* Sites : Flat bones include : (1) Skull bones (2) Scapula (3) Sternum

* Characters :

a flat bone consists of 2 thin layers of compact bone separated by a layer of cancellous bone

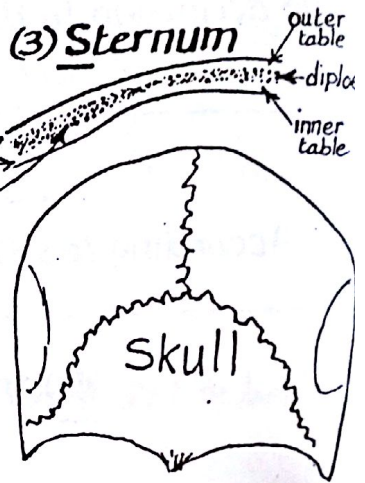
* Functions : flat bones are required to:

- (1) protect vital structures e.g skull bones protect the brain
- (2) provide broad surfaces for muscular attachments

N.B : in case of the skull:- the outer compact bony layer is called outer table.

-> inner " " " " " inner table.

-> middle spongy " " " " diploe.

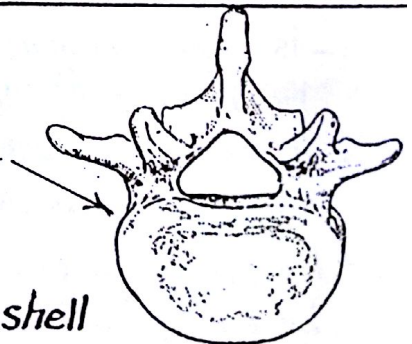


4- Irregular bones

* Sites : (1) some skull bones (2) hip bone (3) vertebrae

* Characters :

- (1) they have irregular shape.
- (2) they are formed of spongy bone covered by a thin shell of compact bone.

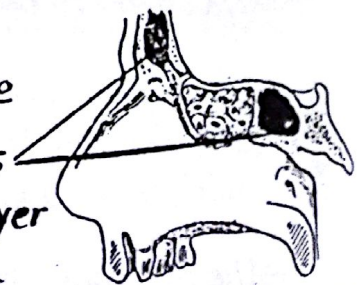


(5) Pneumatic bones

* they include some of the skull bones around the nose which contain air cavities called paranasal sinuses

* N.B : in the pneumatic skull bones, the intermediate spongy layer (diploe) is absorbed and replaced by an air-filled space.

* Functions : (1) they decrease the weight of the skull (2) they give resonance to voice (3) they have highly vascular mucous membrane which produces warming of the inspired air.



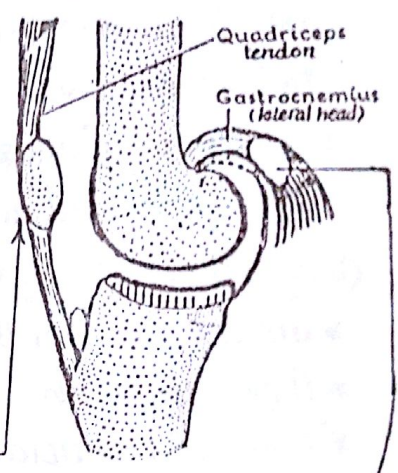
(6) Sesamoid bones



* They are nodules of bone or fibrocartilage that develop in certain tendons when they rub on convex bony surface or subjected to pressure. They are closely related to joints.

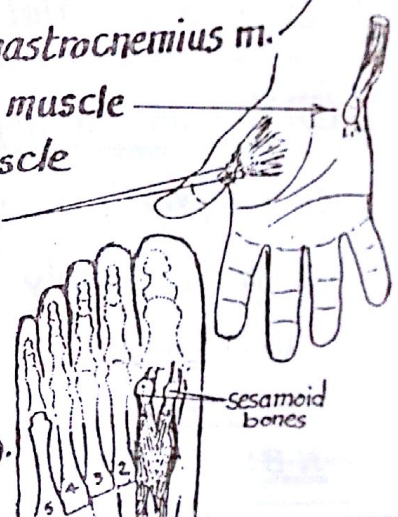
* Functions:

- (1) they reduce friction to which the tendon is subjected.
- (2) " " pressure " " " " " " " "
- (3) " help to retain the blood supply of the tendons.
- (4) " may alter the direction of pull of the muscle

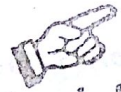

* Examples:

- (1) patella: embedded in the tendon of quadriceps muscle. (it is the largest sesamoid bone in the body).
- (2) Fabella: embedded in the tendon of origin of lateral head of gastrocnemius m.
- (3) pisiform bone: embedded in the tendon of flexor carpi ulnaris muscle
- (4) 2 sesamoid bones " " " " " adductor pollicis muscle at the metacarpophalangeal joint of the thumb.
- (5) " " " " " metatarsophalangeal joint of the big toe in the tendon of flexor hallucis brevis m.
- (6) Some sesamoid bones may be present in other tendons in the sole of the foot (may be mistaken as fractured bones).



VASCULAR SUPPLY OF BONES



(A) Arterial Supply of long bones:

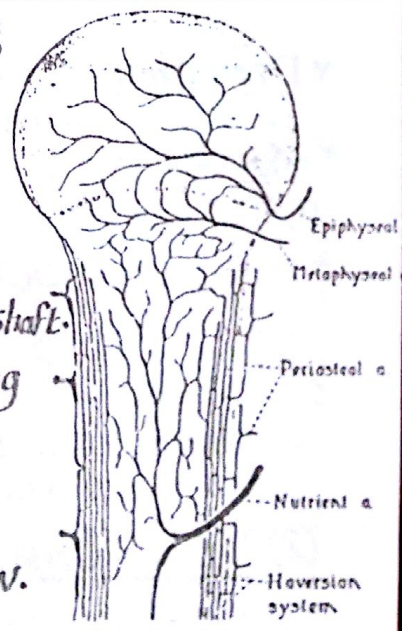
(1) Nutrient artery:

* it is a large artery which enters the shaft of the long bone through the nutrient foramen present about the middle of the shaft.
 * it reaches the medullary cavity where it divides into ascending and descending branches which pass towards the upper and lower metaphyses of the bone

* It supplies the inner zone of the shaft & also the bone marrow.

(2) Epiphyseal arteries:

* they enter the epiphyses supplying the outer shell of compact bone as well as the inner spongy bone.



(3) Metaphyseal arteries :

- * they supply the metaphyses and are derived from the nutrient a. (internally)
the muscular aa. (externally)
- * in children (before ossification of the epiphyseal cartilage), the metaphyseal aa. are end arteries so, their thrombosis in osteomyelitis (bone infection) will lead to bone necrosis.
- * in adults (after ossification of the epiphyseal cartilage) they anastomose with the epiphyseal arteries.

(4) Periosteal arteries :

- * are derived from the vascular plexuses of the periosteum.
- * they supply most of the thickness of the cortex.
- * they are essential for the healing process of bone after fracture.

N.B : Short, flat and irregular bones are supplied by (a) periosteal aa. (main supply)
(b) nutrient a.

(B) Venous drainage : by veins that accompany the arteries of the bone.

(C) Lymphatic drainage : bones are devoid of lymphatic vessels.

(D) Nerve Supply of bone : bone is supplied by :

(1) Sensory nerve fibres : supply the bone and its covering periosteum.

(2) Sympathetic Vasomotor fibres : accompany the arteries supplying the bone.

N.B : the sensory fibres are more numerous at the articular ends of long bone.

Bone Marrow

* Definition : it is the soft C.T lying in the medullary cavities of long bones as well as in the spaces between the trabeculae of cancellous bone

* Types :

(1) Red bone marrow :

- is haemopoietic i.e. Capable of formation of all blood cells.
- in the foetus & till the age of 2 years all bone marrow is red then gradually replaced by yellow marrow.
- in the adult, it is restricted to the bones of the axial skeleton, clavicles, scapulae as well as the cancellous ends of long bones.

(2) Yellow bone marrow :

- it is formed mostly of adipose tissue and has no haemopoietic function but has a potential power of conversion to active haemopoietic tissue in response to severe haematological stresses e.g. blood loss.

* Definition: it is the dense fibrocellular membrane which covers the outer surface of bone.

* Structure: it is formed of 2 distinct layers:

(1) outer fibrous layer: formed of dense white fibrous tissue.

(2) inner cellular : : » » elastic fibres and dormant osteoblasts & is richly supplied by blood vessels & nerves.

* Function:

(1) it acts as a medium for attachment of muscles, tendons & ligaments to the bone.

(2) it forms a protective covering & has a nutritive function to the cortex of » ».

(3) its osteogenic activity is essential for healing of fractured or diseased bone.

Direction of nutrient foramina of long bones

* The direction follows the following rule:

(1) to the elbow the arteries go (downwards in humerus & upwards in radius & ulna).

(2) from the knee » » (upwards in femur & downwards in tibia & fibula).

(3) towards the acromion in the clavicle.



Growing ends of long bones

The reverse of the previous rule i.e.:

(1) the growing ends of the upper limb are — the upper end of humerus.
 — lower ends of radius & ulna.

(2) » » » » » lower limb are — the lower end of femur.
 — upper ends of tibia & fibula.

(3) » sternal end of the clavicle.

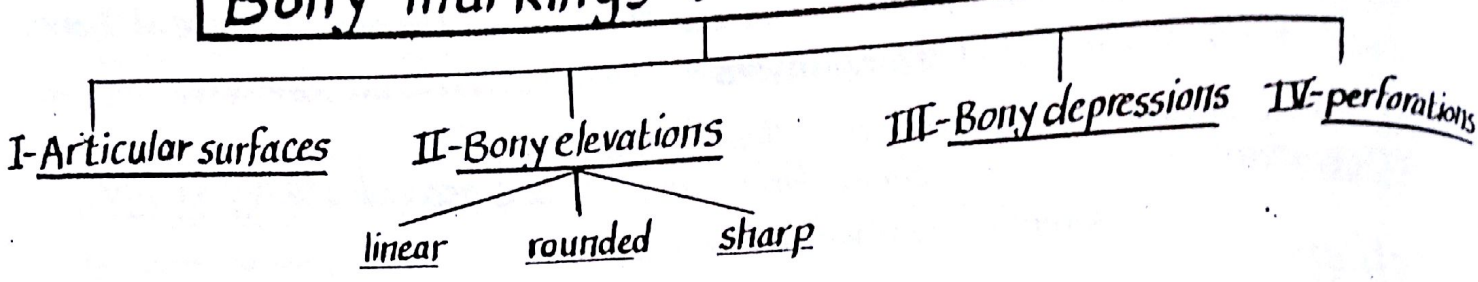
OSSEIFICATION

* Definition: it is the process of bone formation

* Types: it has 2 types: membranous ossification & cartilagenous ossification.

membranous ossification	cartilagenous ossification
- Bones are developed directly from embryonic mesenchymal membrane	- bones are first modelled in the form of cartilage which is replaced by bone tissue
- The process of ossification occurs rapidly.	- the process of ossification occurs at leisure (slowly).
- it occurs in certain bones which are required urgently for support or protection of vital organs e.g the clavicle and the bones of the vault of skull.	- it occurs in all other bones of the skeleton.

Bony markings (Features of bones)

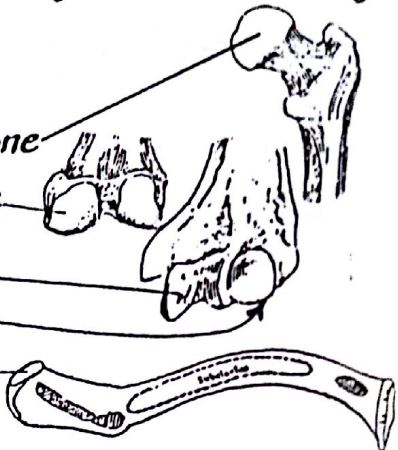


I- Articular surfaces:

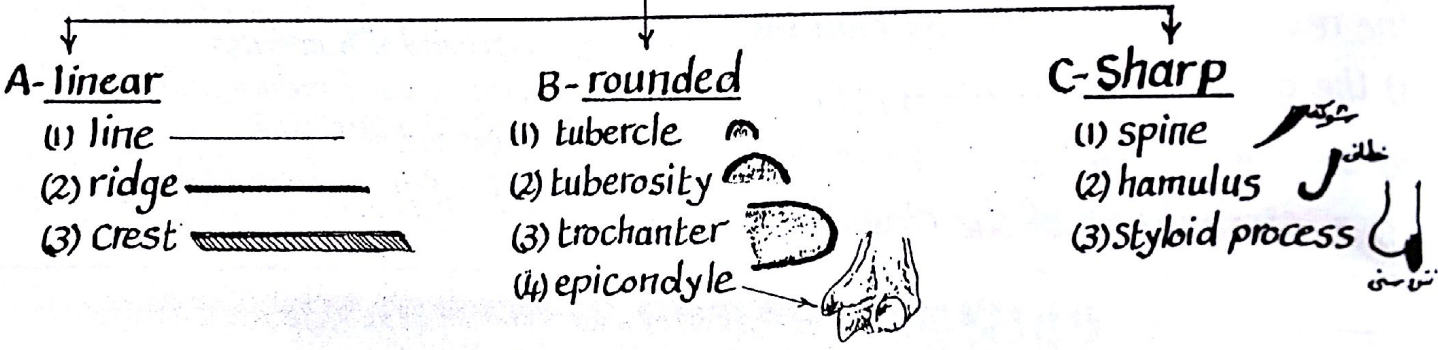
- an articular surface is a smooth bony impression which is covered by articular cartilage & enters in the formation of a synovial joint.

- articular surfaces include the following forms:

- (1) head: a hemispherical articular surface at one end of the bone
- (2) Condyle: a rounded articular surface at one end of the bone
- (3) trochlea: (بكرة): pulley shaped articular surface.
- (4) Capitulum: (رأس منبر): a small spherical articular surface.
- (5) Facet: (سطح منبسط): a small flat or concave articular surface.

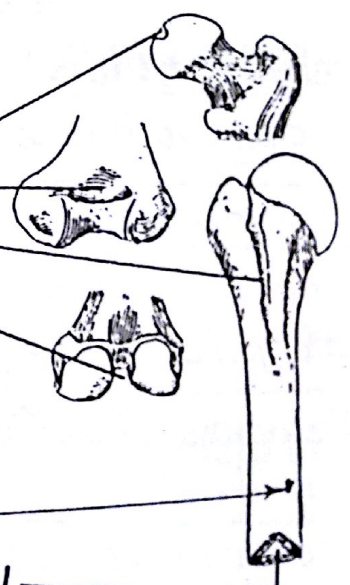


II- Bony elevations




III- Bony depressions

- (1) Pit or fovea: a small depression: e.g. pit of head of femur
- (2) Fossa: a large concave depression: e.g. olecranon fossa
- (3) groove or sulcus: a linear depression e.g. bicipital groove
- (4) notch: indented part of a bone e.g. intercondylar notch



IV- Perforations

- (1) Foramen: a hole in the bone e.g. nutrient foramen
- (2) Canal: a long perforation in the bone e.g. medullary canal
- (3) Fissure: a long cleft in a bone or between 2 bones.



JOINTS

* Definition : a joint or articulation is the meeting of two or more bones of the skeleton (where movements may or may not be allowed).

* Classification : joints are classified according to the nature of the tissue between the articulating bones into 3 types : Fibrous, Cartilagenous & synovial.

A- FIBROUS JOINTS

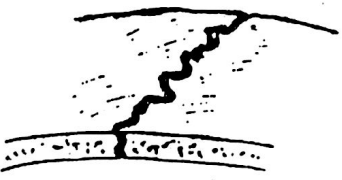
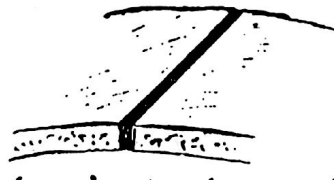

* Characters :

- (1) The opposed bony surfaces are connected together by fibrous tissue.
- (2) There is NO joint cavity between the articulating bones.
- (3) No movements is allowed " " " "

* Types : there are 3 types of fibrous joints

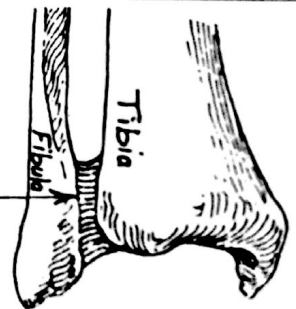
- Sutural.
- Syndesmosis.
- Gomphosis.

1) Sutural fibrous joints : occurs between flat bones e.g skull bones where the opposed edges are connected by sutural ligaments. Sutures may be:

A- Serrate suture	B- plane suture	C- Squamous suture
		
<p>- the bony margins have saw-like edges e.g sagittal suture of the skull</p>	<p>there is simple apposition between the bony edges e.g interpalatine suture of skull</p>	<p>one bony edge overlaps the other e.g temporo-parietal suture of the skull.</p>

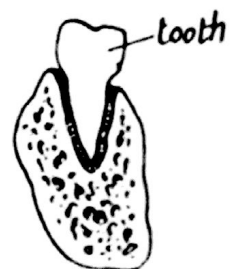2) Syndesmosis :

- the opposed bony surfaces are connected by an interosseous ligament.
- Example : the inferior tibio-fibular joint



3) Gomphosis (peg & socket) :

- it is the articulation between a conical process (peg) and a deep socket.
- Example : the articulation between the root of the tooth and the bony socket where they are connected by fibrous ligament.



B- CARTILAGENOUS JOINTS

20

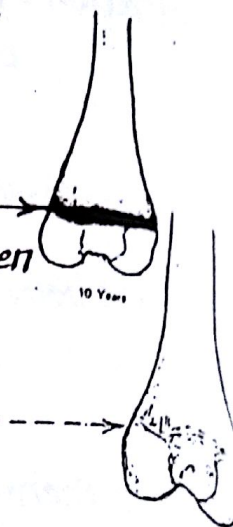
* Characters :

- (1) the articulating bones are connected together by an intervening cartilage.
- (2) there is no joint cavity.
- (3) No (or limited) movements is allowed in the joint.

* Types : there are 2 types of cartilagenous joints : 1^{ry} & 2^{ry} .

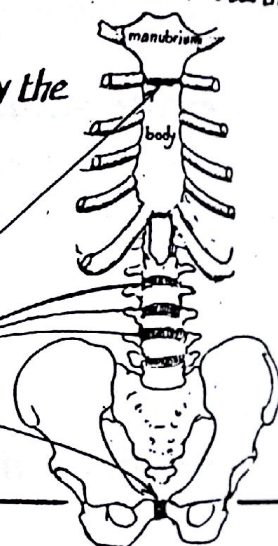
1- Primary Cartilagenous joint (Synchondrosis) :

- the bones are connected by a plate of hyaline cartilage
- it is represented by the epiphyseal plate of cartilage intervening between the epiphysis & metaphysis of long bones
- this type has no joint cavity and does not allow any movement.
- it is a temporary joint which disappears in adulthood by ossification



2- Secondary Cartilagenous joints (Symphyses) :

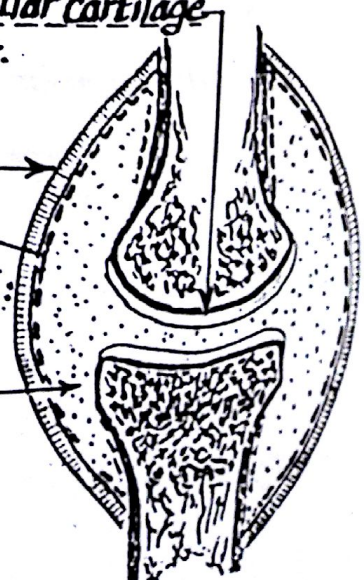
- the opposed surfaces of the articulating bones are connected by a disc of white fibrocartilage
- these joints are generally permanent (remain throughout life).
- There is no joint cavity and only limited movement is permitted by the compressibility of the cartilagenous discs.
- Examples : 2^{ry} cartilagenous joints include the articulations present in the median plane of the body e.g :
 - (1) the joint between the manubrium & body of sternum
 - (2) the intervertebral discs between the vertebral bodies.
 - (3) the symphysis pubis between the 2 hip bones



C- SYNOVIAL JOINTS

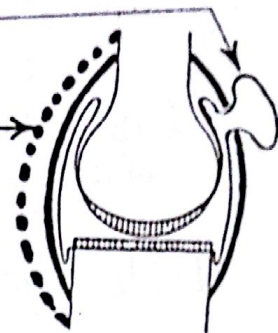
* Structure & characters :

- (1) The opposed articulating surfaces are covered by hyaline articular cartilage which is smooth, compressible & highly resistant to wear & tear.
- (2) the articulating bony ends are connected by a tubular fibrous sheath formed of collagenous fibres called the Fibrous capsule
- (3) the fibrous capsule is lined internally by Synovial membrane which lines the whole interior of the joint with the exception of:
 - (a) the articular surfaces
 - (b) intra-articular discs or menisci.
- (4) There is joint cavity containing synovial fluid which is a lubricant fluid secreted by the synovial membrane.

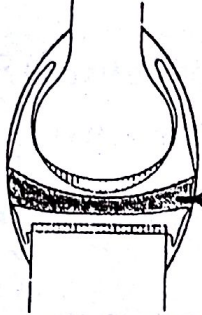
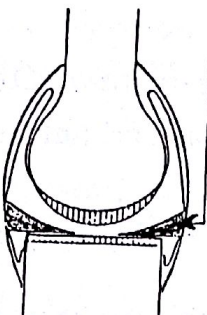
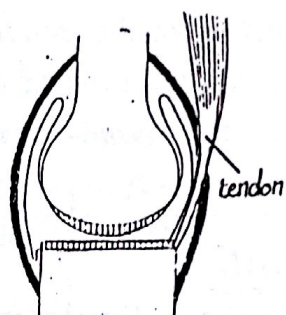
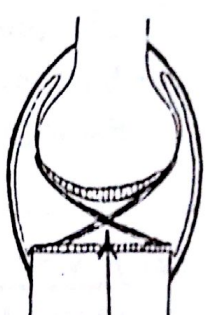


(5) the Capsule may contain openings through which the synovial membrane may protrude forming synovial bursa

(6) The fibrous capsule is reinforced externally by accessory ligaments formed of unstretchable collagenous fibres which connect the articulating bones outside the capsule



(7) Some synovial joints contain Intracapsular Structures as

(a) Articular disc	(b) Menisci	c- tendons of muscles	d- Ligaments
			
Formed of Fibrocartilage it divides the cavity completely or incompletely into 2 compartments e.g sternoclavicular j.	are semilunar plates of Fibrocartilage present inside the knee joint	as the biceps tendon inside the shoulder joint & popliteus tendon inside the knee joint.	as the cruciate ligaments inside the knee joint.

(8) Movements is always possible in the synovial joints, ranging from a very limited sliding movement to a wide range of angular movement (see page 24).

(9) Nerve Supply of the joint (Hilton's law):

- synovial joints are innervated by the same nerves which supply the muscles acting on these joints
- the nerves supplying a joint are sensory & called articular nerves which are distributed to the fibrous capsule & related ligaments. They carry pain & movement impulses from the joint to the C.N.S.

(10) Blood Supply of Synovial joints:

- * the blood supply of most synovial joints is derived from network of arteries forming anastomosis around the joint
- * From this anastomosis articular branches pierce the capsule forming plexus in the synovial membrane to supply all intracapsular structures except the articular cartilages which are avascular



Classification (Types) of Synovial Joints

I - According to shape of articulating bones

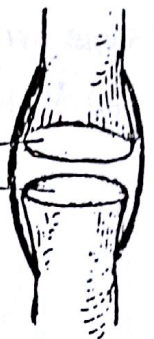
II - according to number of articulating bones

III - according to axis of movement

I - Classification according to the shape of the articulating bones :

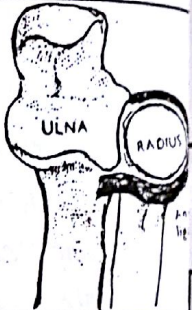
(1) Plane joint :

- the opposed articular surfaces are nearly flat
- the movements permitted are only sliding motion
- Examples : (a) acromio-clavicular joint (b) sacro-iliac joint (c) intercarpal & intertarsal joints.



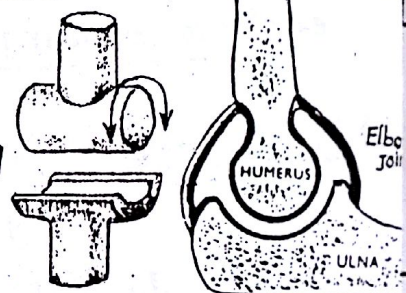
(2) Pivot Joint :

- in this type the articulating surfaces consist of a central bony pivot surrounded by a ring which is partly bony & partly ligamentous.
- the movements allowed are only rotatory around a longitudinal axis.
- Examples : (a) superior radio-ulnar joint (b) the atlanto-axial joint.



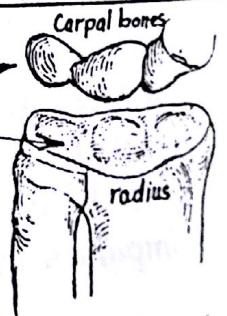
(3) Hinge joint :

- the articulating surfaces resemble the hinge of the door
- the movements occur around a transverse axis allowing flexion & extension only
- Examples : (a) elbow joint (b) ankle joint.



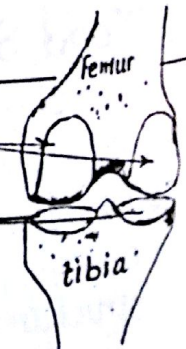(4) Ellipsoid joint :

- the articular surfaces consist of
 - (a) convex oval surface
 - (b) elliptical convex surface
- Movements are permitted in 2 planes (around 2 axes) allowing flexion & extension around one axis and abduction & adduction around another perpendicular axis.
- Example : wrist joint.



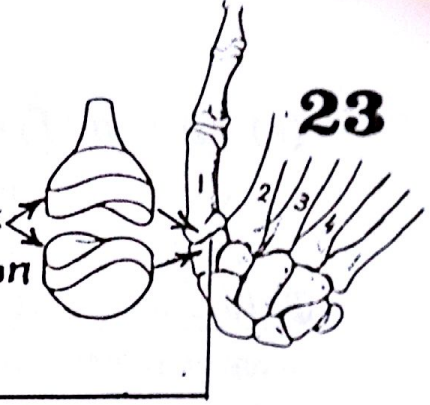
(5) Condylar (bicondylar) joint :

- the articular surfaces consist of
 - 2 separate convex condyles
 - 2 concave articular surfaces
- Movements occur mainly in one plane (flexion & extension) but limited movement takes place in another plane (rotation).
- Example : knee joint.



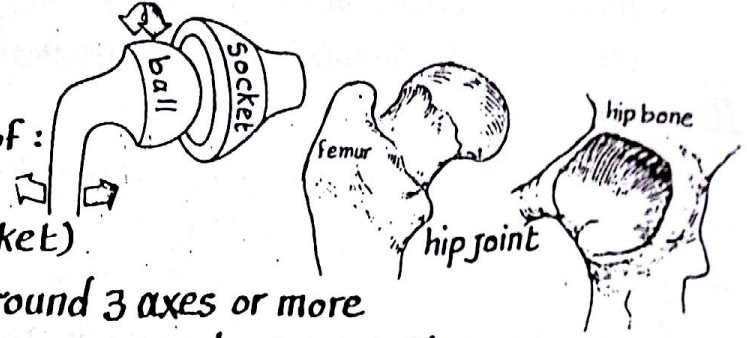
(6) Saddle joint :

- the opposed articular surfaces are each concavo-convex
- the movements permitted are flexion & extension, abduction & adduction in addition to some rotation.
- Example : Carpo-metacarpal joint of the thumb.



(7) Ball and socket joint :

- the articulating surfaces consist of :
 - (a) a rounded head (the ball)
 - (b) cup-shaped concavity (the socket)
- the movements in this type occur around 3 axes or more allowing :
 - (a) flexion & extension.
 - (b) abduction & adduction.
 - (c) med. & lat. rotation.
 - (d) circumduction.
- Examples : Shoulder joint & hip joint .



II- Classification according to axes of movement

(1) uniaxial joints	(2) Bi-axial joints	(3) poly-axial joints
permitting movements around a single axis e.g (a) hinge joint } شرح بالتفصيل (b) pivot joint }	permitting movements around 2 perpendicular axes e.g. (a) condylar joint (b) Ellipsoid } شرح بالتفصيل (c) Saddle }	permitting movements around more than 2 axes e.g the ball & socket joints. شرح بالتفصيل

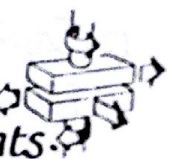
III- Classification according to number of articulating bones

(1) simple joint	(2) Compound joint	(3) Complex joint
consists of 2 articulating bones only e.g shoulder joint	consists of more than 2 articulating bones e.g elbow joint	contains intracapsular articular disc or menisci e.g knee joint.

Movements of Synovial joints

* 4 kinds of movements are allowed in synovial joints :

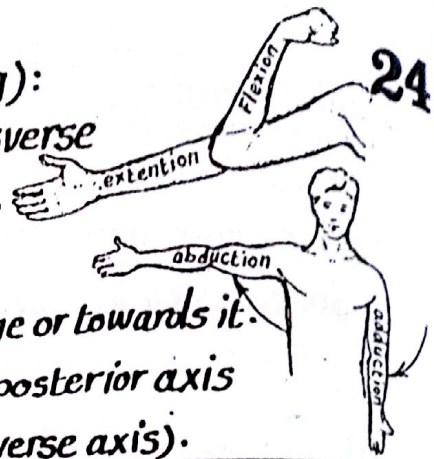
I- Gliding movement : is the simplest type, where one articular surface glides over another. This movement occurs in plane joints.



II- Angular movement :

is the movement in which there is an increase or decrease of the angle between the articulating bones. Angular movement includes :

(A) Flexion / Extension (bending and straightening):
are the movements which occur around a transverse axis as occurs in hinge joints e.g elbow joint.



(B) Abduction / Adduction :

- are movements of the limb away from the median plane or towards it.
- these movements occur around a more or less anteroposterior axis (except in the thumb where they occur around a transverse axis).

III- Rotation :

- it is the movement of the bone around a longitudinal axis which may be:

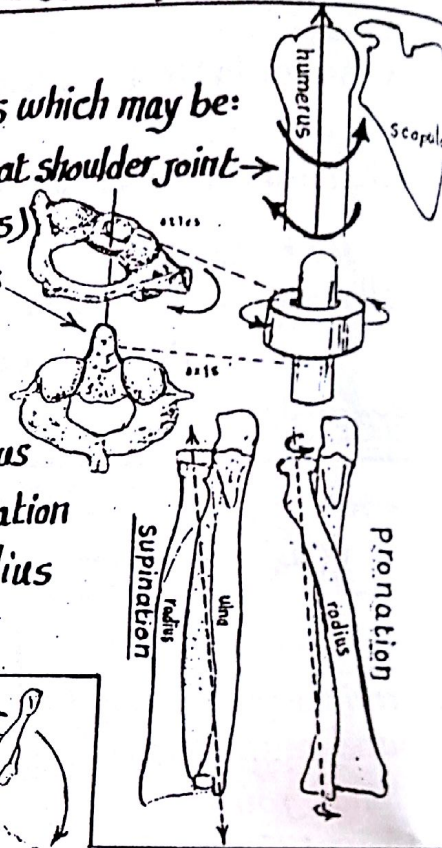
(A) its own longitudinal axis : e.g rotation of the humerus at shoulder joint →

(B) part of another bone : e.g 1st cervical vertebra (atlas)

turns round the longitudinal axis of the odontoid process of the 2nd cervical vertebra (axis)

(C) the axis of rotation may be oblique to the long axis of

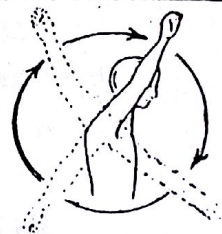
the bone : e.g in the movement of rotation of the radius on the ulna in supination and pronation, the axis of rotation is a line extending from the centre of the head of the radius to the centre of the styloid process of ulna.



IV- Circumduction :

- it is a combination of flexion, abduction, extension and adduction movements which follow one another in succession.

- it occurs between the head of a bone and its articular cavity in the ball and socket joints e.g shoulder and hip joints.



Factors affecting the Stability of joints

(1) Bony factors : the shape & contour of the articular surfaces & their fitting together:

- joints having well fitting articular surfaces e.g hip joint, are more stable than those having poorly fitting surfaces e.g shoulder joint (the head of humerus is larger than the glenoid cavity).

(2) Capsular & ligamentous factors : the more the strength & thickness of the fibrous capsule the more stable is the joint because these structures prevent over movement & guard against sudden accidental stresses at the joint.

(3) Muscular factors :




the contraction of the muscles around the joints keeps the articular surfaces in firm contact so, the more stronger are the muscles, the more stable is the joint.

MUSCULAR TISSUE

* Definition: muscles are the contractile elements of the human body
 * Properties: muscular tissue has the property of becoming short in response to an appropriate stimulus. This property is due to:

- (1) the high excitability of the plasma membrane of the muscle cells.
- (2) the presence of contractile protein (actomyosin) inside the cell.

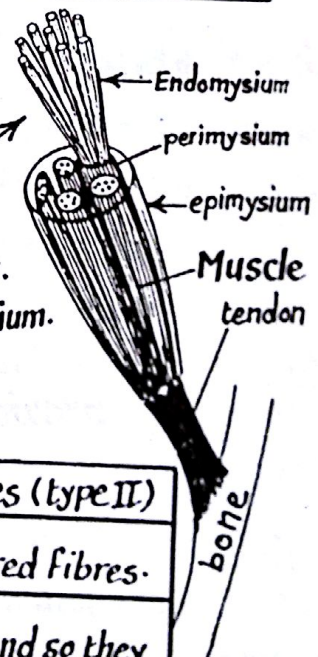
* Types (varieties) of muscles: there are 3 types: skeletal, smooth & cardiac.

	1-Skeletal muscle	2-Smooth muscle	3-Cardiac muscle
Distribution	attached to the bones of the skeleton (hence the name skeletal).	present in the walls of viscera and blood vessels (hence the name visceral)	present in the walls of the heart (myocardium).
Microscopic appearance	 the muscle fibres are multinucleated & show transverse striations	 the muscle fibres are spindle-shaped, uninucleated & show no striations	 muscle fibres are uninucleated, striated, branch & fuse together.
Stimulation	neurogenic i.e in response to nerve impulses	neurogenic or myogenic (in response to stretch of the wall).	neurogenic, by impulses from the S-A node
Nerve Supply	Somatic motor nerve	autonomic	autonomic
Control	under voluntary control	involuntary	Involuntary

SKELETAL MUSCLES

* Structure:

- the skeletal muscle is formed of large number of muscle fibres each of which is surrounded by a fine sheath called Endomysium
- the muscle fibres are arranged in bundles surrounded by perimysium.
- the whole muscle is surrounded by strong fibrous sheath called epimysium.



* Types of skeletal muscle fibres:

(1) Red muscle fibres (type I)	(2) White muscle fibres (type II)
more primitive than white fibres	more elaborate than red fibres.
Contain myoglobin pigment and so they appear red.	Contain no myoglobin and so they are pale in appearance.
present in deeply seated muscles.	present in the superficial muscles.
are slowly contracting.	are rapidly contracting.

Attachment of skeletal muscles

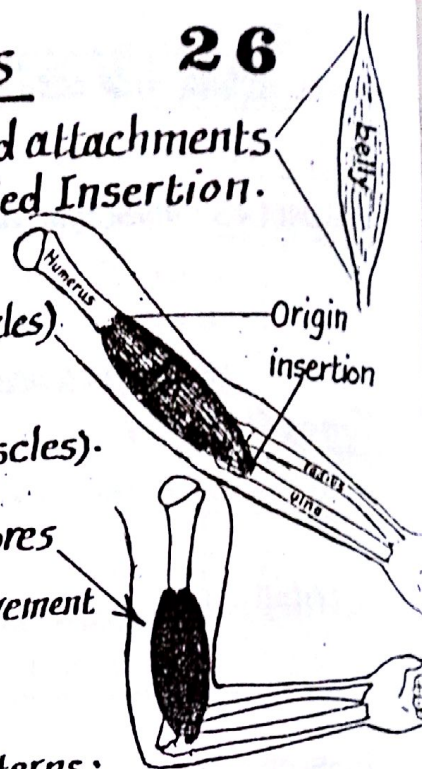
26

- Each muscle has a fleshy part called belly & 2 ends called attachments. One attachment is called the Origin while the other is called Insertion.

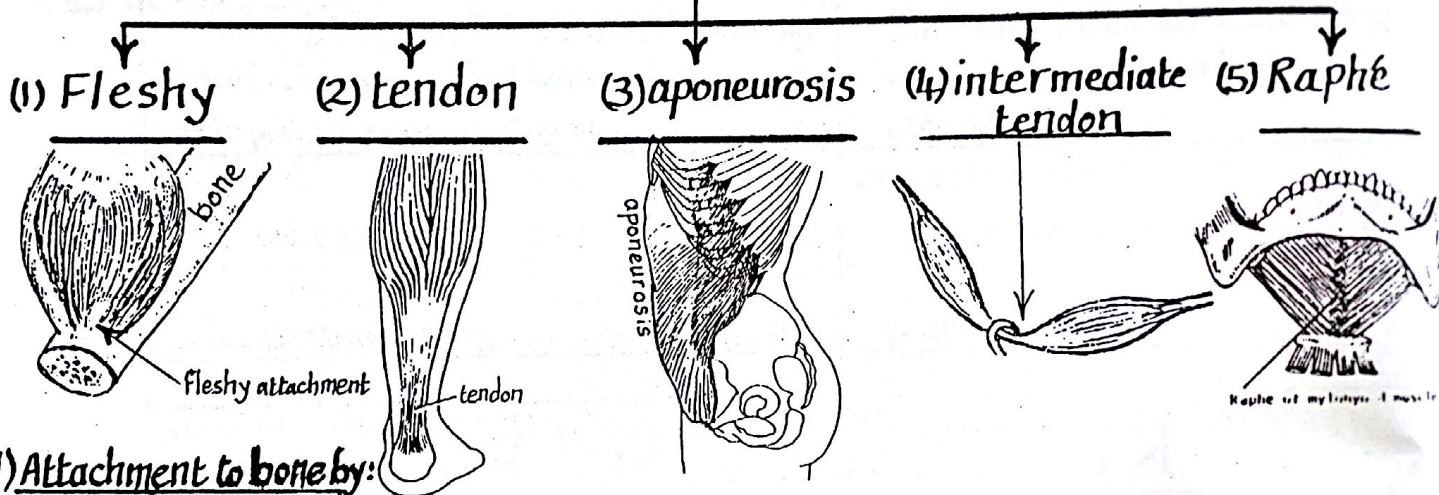
(1) The Origin: (a) is the more fixed attachment.
(b) is the proximal attachment (in limb muscles).

(2) The Insertion: (a) the more mobile attachment.
(b) the distal attachment (in limb muscles).

- Contraction of the muscle leads to shortening of its fibres & pulls the insertion towards the origin thus produces movement.



each of the 2 attachments may take one of the following patterns:

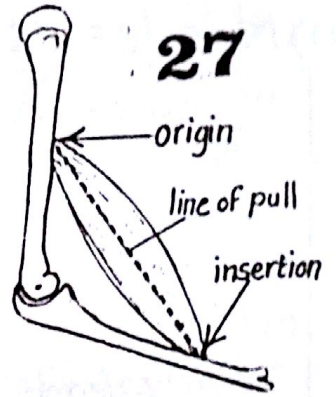


1) Attachment to bone by:

- (a) Fleshy attachment: the muscle is attached to bone directly by fleshy fibres.
- (b) Tendon: formed of condensed bundles of collagenous fibres. It may be rounded (cord-like) or flat (ribbon-like). It concentrates the action of the muscle to a small area in the bone.
- (2) Aponeurosis: a flattened sheet of fibrous tissue developing in flat muscles to provide a wide attachment.
- (3) Intermediate tendon: a rounded tendon connecting 2 fleshy bellies together.
- (4) Raphé: a fibrous band in the median plane formed of interlacement of collagenous fibres of 2 identical muscles e.g. mylohyoid raphé.
- (5) Cutaneous attachment: some muscles e.g. muscles of the face are attached to the dermis of the skin.
- (6) Attachment to cartilage: as in the muscles of the larynx e.g. cricothyroid muscle.

Form of muscles

27



The form of the muscle depends on the arrangement of its fibres in relation to the line of pull of the muscle which is a line extending between the origin & insertion of the muscle.

Muscles are classified according to the arrangement of their fibres into 4 main forms:


(A) Muscles with fibres parallel to the line of pull

(1) quadrilateral




e.g. pronator quadratus m.

(2) strap-like



(a) with fleshy insertion e.g. sartorius m.
(b) » tendinous » e.g. rectus abdominis m.

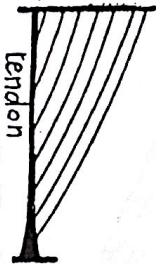
(3) Fusiform



e.g. lumbrical muscles

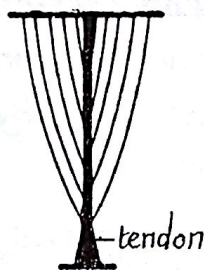
B) Muscles having fibres oblique to the line of pull with pennate arrangement:

(1) unipennate



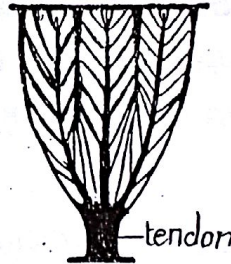
The fibres are attached to one side of the tendon (like half a feather) e.g. flexor pollicis longus m.

(2) Bipennate



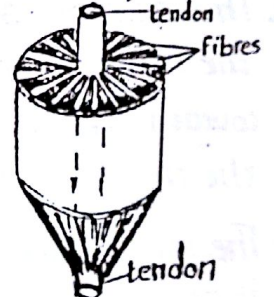
The fibres are attached to both sides of the tendon (like complete feather) e.g. rectus femoris m.

(3) multipennate



a series of bipennate bands lying side by side & have a common tendon e.g. deltoid m.

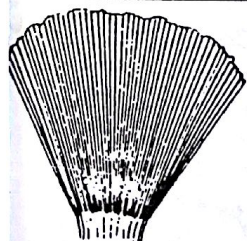
(4) Circumpennate



The fibres converge from all sides on a centrally placed tendon. e.g. tibialis post.

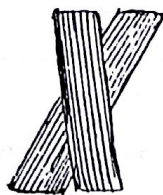C) Muscles having fibres oblique to the line of pull without pennate arrangement:

(1) Triangular



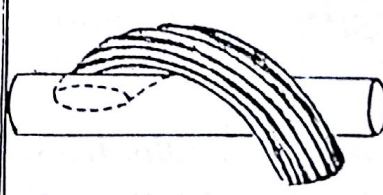
e.g. temporalis m.

(2) Cruciate (X-shaped)



e.g. masseter m.

(3) spiral



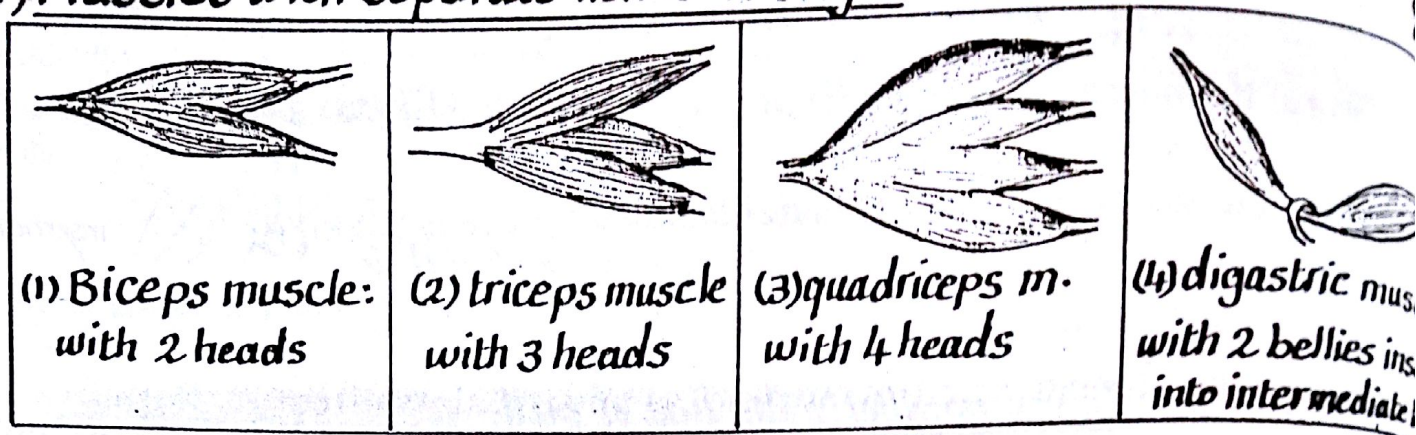
e.g. supinator m.

(4) circular



e.g. orbicularis oris muscle

(D) Muscles with separate heads of origin:

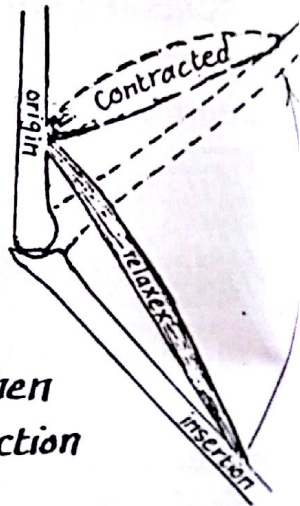


Mechanics of muscle form

- (1) In muscles with fibres parallel to the line of pull, shortening (contraction) of the muscle fibres results in equal shortening of the whole muscle thus allowing maximal range of movement.
- (2) In muscles with fibres oblique to the line of pull, shortening of the muscle fibres results in less shortening of the muscle as a whole.

Action of muscles

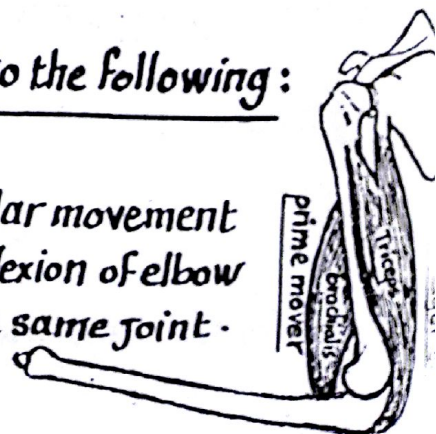
- * The action is the movement produced by the contraction of the muscle leading to approximation of the bone of insertion towards the bone of origin thus moving the joint(s) crossed by the muscle.
- * The muscle always produces a movement in any joint it crosses & when it crosses more than one joint (2 or more) it produces its main action on the distal joint.
- * The range of contraction (shortening) depends on the length of muscle fibres, the longer the muscle fibres, the greater the range of mobility.
- * The power of contraction depends on the number of muscle fibres: the more the number of fibres, the greater the power of contraction thus multipennate muscles are the most powerful.



* Muscles are classified according to their action into the following:

(1) Prime movers:

a prime mover is a muscle which initiates a particular movement at the desired joint e.g brachialis is the prime mover of flexion of elbow while triceps m. is the prime mover of extension of the same joint.



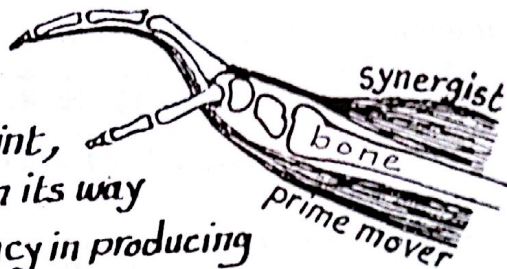
(2) Antagonist or opposing muscles:

29

these are muscles which oppose the action of prime movers. For example, in flexing the elbow joint by brachialis m. (prime mover of flexion), the triceps muscle opposes the brachialis and hence it is called an antagonist.

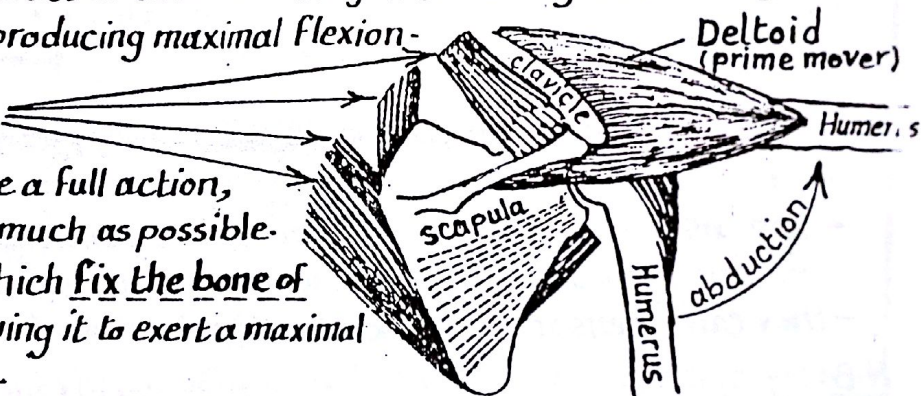
(3) Synergists or Synergistic muscles:

- when a prime mover crosses over more than one joint, contraction of this muscle will move all the joints in its way from origin to insertion and accordingly, its efficiency in producing its full action on the desired joint is reduced.
- The synergistic muscles are those muscles which help the prime mover muscle by stabilizing the subsidiary joints (preventing the unwanted movement at these joints) thus allowing the prime mover to produce maximal action on the desired joint.
- For example: flexion of the fingers by the flexor digitorum muscles which cross over the wrist is associated with flexion of the wrist in addition to the fingers. To eliminate the unwanted flexion at the wrist, the synergistic muscles which are the extensors of the wrist contract to stabilize the joint allowing the flexor digitorum muscles to act on the fingers producing maximal flexion.



(4) Fixators (Stabilizers):

- For the prime mover to produce a full action, its origin should be stable as much as possible.
- Fixator muscles are those which fix the bone of origin of the prime mover allowing it to exert a maximal action on the bone of insertion.

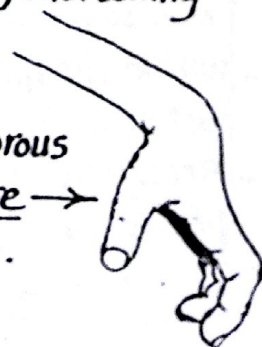


For example: the muscles which fix bones of shoulder girdle (clavicle & scapula) allow the deltoid m. to produce a full action on the humerus in performing abduction.

Contraction & Contracture

Contraction: is a physiological active process resulting in a temporary shortening of the muscle fibres and is followed by its relaxation.

Contracture: is a pathological condition in which the muscle fibres become permanently shortened & may be replaced by fibrous tissue resulting in abnormal position e.g. Volkman's Contracture due to ischaemic fibrosis of the flexor muscles of forearm.



- * It is the process of recording the electric changes inside the muscle during its contraction.
- * It is done by placing 2 electrodes on the surface of the muscle or within its substance.
- * It allows analysis of the function of the muscle during motion e.g. at what stage of movement the muscle exhibits the greatest activity.

* Innervation of skeletal muscles:

- Each skeletal muscle receives one or more nerves which usually accompany the blood vessels of the muscle forming neurovascular bundle.
- the neurovascular bundle enters the deep surface of the muscle near its origin at specific small opening called neurovascular hilum.
- A nerve entering the muscle consists of both motor & sensory fibres:

(A) Motor fibres:

- are axons of the anterior horn cells of the spinal cord.
- they break up into terminal branches inside the muscle.
- each branch ends on an individual muscle fibre forming an expansion termed the motor end plate.

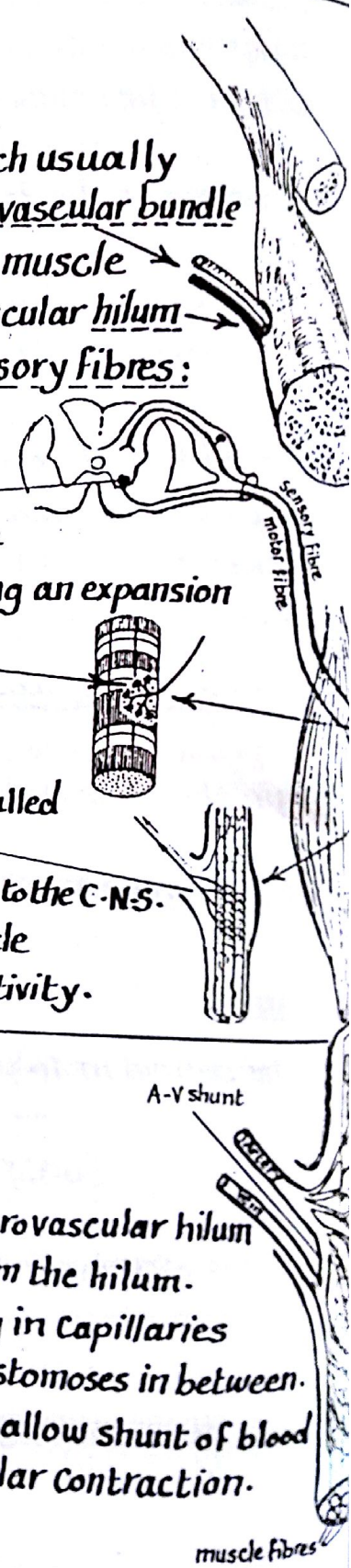
(B) Sensory fibres:

- are axons of posterior root ganglion cells.
- are distributed to specialized sensory end organs called muscle spindles placed between the muscle fibres.
- they carry sensory (proprioceptive) impulses from the muscle to the C.N.S.

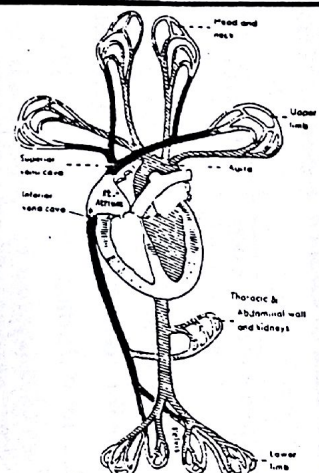
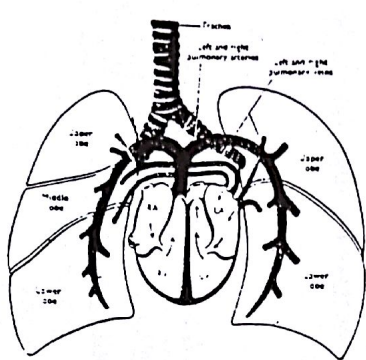
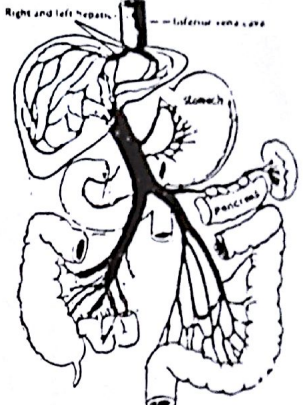
N.B: Sympathetic Vasomotor Fibres also supply the muscle to regulate the circulation according to the muscle activity.

* Blood Supply of skeletal muscles:

- skeletal muscles have rich vascular supply.
- the main blood vessels enter the muscle through the neurovascular hilum but some subsidiary arteries enter the muscle away from the hilum.
- within the muscle, the arteries divide repeatedly ending in capillaries between the individual muscle fibres with transverse anastomoses in between.
- Arterio-venous shunts are present inside the muscle to allow shunt of blood if the capillary circulation is obstructed during muscular contraction.



BLOOD CIRCULATION

1-Systemic circulation	2-Pulmonary circulation	3-Portal circulation
 <p style="font-size: small;">Labels: Head and neck, Upper limb, Aorta, Thoracic & abdominal wall and kidney, Lower limb, Superior vena cava, Inferior vena cava, RT. Atrium.</p>	 <p style="font-size: small;">Labels: Trachea, Left and right pulmonary arteries, Left and right pulmonary veins, Superior vena cava, Inferior vena cava, Right and left ventricle.</p>	 <p style="font-size: small;">Labels: Right and left hepatic, Inferior vena cava, Stomach, Pancreas, Intestine.</p>
<p>* Aim : Carrying oxygenated blood from the heart to all tissues of the body</p>	<p>* Aim : Carrying deoxygenated blood from the heart to the lungs to be oxygenated</p>	<p>* Aim : Carrying the venous blood from the G.I.T to the liver to be purified before it returns to the heart</p>
<p>* Begins : From Lt. ventricle where oxygenated blood passes to the aorta & its branches to all tissues of the body ending in capillaries.</p>	<p>* Begins in the Rt. ventricle where deoxygenated blood passes through the pulmonary trunk then through the 2 pulmonary arteries to enter the 2 lungs.</p>	<p>* Begins as capillaries in the walls of the G.I.T which collect to form the portal v. that enters the liver & divides repeatedly to end in sinusoid</p>
<p>* In the tissues : exchange of materials and gases takes place between the capillaries and tissue cells & blood becomes deoxygenated.</p>	<p>* In the lung alveoli : the blood gets rid of CO_2 & becomes oxygenated.</p>	<p>* In the liver sinusoids the blood becomes purified & its products of digestion become metabolized by the liver cells</p>
<p>* the deoxygenated blood collects in the veins which finally end in the S.V.C & I.V.C. that open into the right atrium</p>	<p>* the oxygenated blood returns from each lung via 2 pulmonary veins which finally open into the left atrium.</p>	<p>* the purified blood collects from the liver sinusoids into 2 hepatic veins that join the inferior vena cava.</p>

BLOOD VESSELS

ARTERIES

* Definition: they are vessels carrying blood from the heart to the tissues.

* Characters:

- (1) they pulsate with each cardiac systole.
- (2) if an artery is opened, blood is ejected in spurts.
- (3) arteries have thick walls & are devoid of valves.
- (4) in the cadaver, they appear pink in colour & empty.

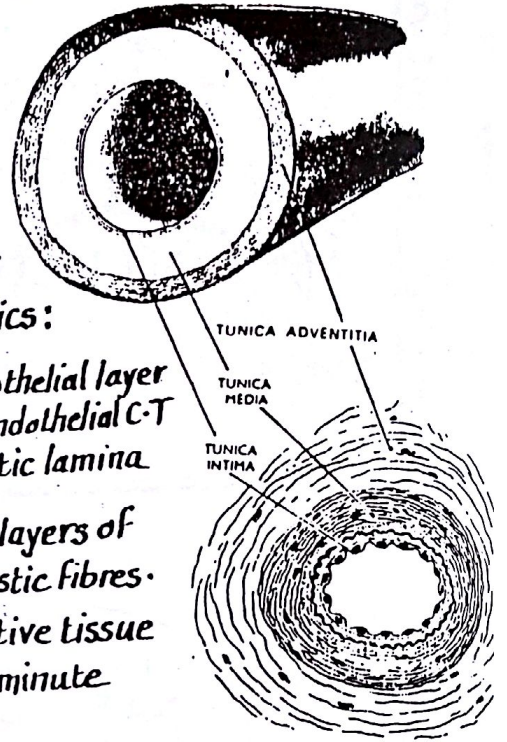
* Structure: the wall of an artery has 3 coats or tunics:

(a) Inner Coat or tunica intima:

it is the smooth lining layer formed of $\left\{ \begin{array}{l} \text{single endothelial layer} \\ \text{little subendothelial C-T} \\ \text{internal elastic lamina} \end{array} \right.$

(b) middle Coat or tunica media: formed of alternate layers of smooth muscle & elastic fibres.

(c) outer Coat or tunica adventitia: formed of connective tissue & contains small blood vessels (vasa vasorum) & the minute nerves which supply the wall of the artery



* Types of arteries: According to their size & structure, arteries are classified into

	1-large-sized arteries (elastic arteries)	2-medium-sized (muscular arteries)	3-Arterioles (minute arteries)
T.S			
General Features	large-sized (ϕ more than one cm). e.g. aorta & carotid a.	medium-sized (ϕ less than one cm) e.g. limb arteries	diameter less than 0.5 mm.
Structure	very thick tunica media with abundant elastic fibres.	thick tunica media, mostly formed of smooth muscle fs.	relatively thick wall of muscle fs. & narrow lumen
Function	the elasticity of its wall allows much expansion of the vessel during systole then recoils during diastole thus converting the intermittent cardiac contractions into a continuous flow.	controls the blood flow to the organs by contraction & relaxation of its muscular wall which is supplied by autonomic vaso motor fibres	-they regulate the blood flow to the tissues acting as precapillary sphincters -They provide the main resistance that determines the arterial blood pressure

*** Course of arteries :**

- Most of the arteries run on the flexor aspect of the body to avoid tension during the movement of the adjacent joints
- Some arteries run a wavy course particularly if they supply expansile or moving organs.

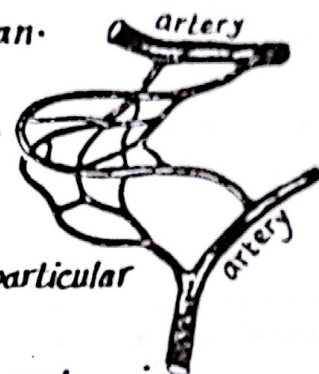
*** Examples of wavy (tortuous) arteries :**

- (1) Facial artery : supplies the face (moves during facial expressions).
- (2) uterine " : " " uterus which enlarges during pregnancy.
- (3) lingual " : " " tongue which is a moving organ.
- (4) splenic " : " " spleen " " " Contractile organ.



Arterial anastomosis

*** Definition :** it is the communication between the branches of neighbouring arteries.

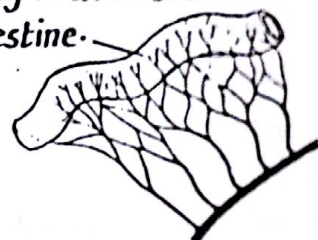
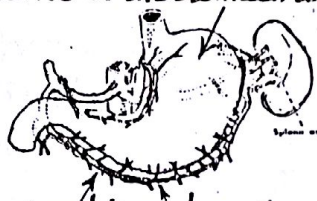

*** Significance :** (1) it allows an alternate pathway for blood supply of a particular area or organ if the main pathway is obstructed.

(2) equalization of pressure in all areas supplied by the anastomosis.

*** Sites :** arterial anastomosis occurs mainly at the following sites :

- (1) around joints where the movements can interfere momentarily with the circulation.
- (2) in the abdomen: between the arteries of the stomach and intestine.
- (3) in the hands & feet.
- (4) at the base of the brain.



*** Types of Arterial anastomosis :**

- (1) actual anastomosis : where arteries meet end to end e.g the arteries supplying the stomach
- (2) potential anastomosis : where minute arterial branches anastomose together e.g most of the limb anastomoses in the region of the joints
- (3) poor anastomosis : here the anastomosis is by terminal arterioles e.g anastomosis between the coronary arteries of the heart.

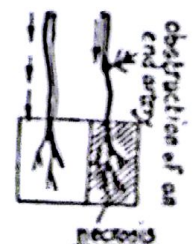
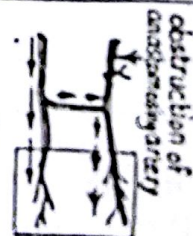N.B : anastomosis provides effective collateral circulation in the following conditions:

- (a) when obstruction of the artery is gradual rather than acute.
- (b) in young age rather than in old age (due to atherosclerosis of vessels).

End Arteries

*** Definition :** they are arteries which do not anastomose with neighbouring arteries & therefore their obstruction leads to ischaemia & necrosis of the supplied tissue.

- * Examples of end-arteries**
- (1) Central artery of the retina.
 - (2) Central arteries of the brain.
 - (3) arteries within kidney & spleen.



*** Arterial Supply of large arteries (vasa Vasorum)**

the arterioles which lie in the tunica adventitia of large-sized arteries are called vasa vasora and arise from the nearby arteries.

*** Nerve Supply of arteries :**

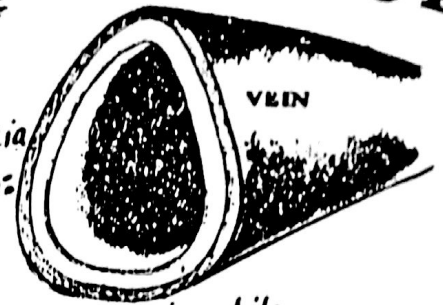
the tunica media (muscular coat) is supplied by sympathetic vasoconstrictor fibres.

II- VEINS

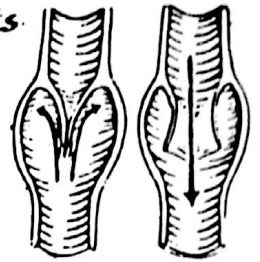
* Definition: they are vessels carrying blood towards the heart.

* Structure: the wall of the vein, like that of the artery, is formed of 3 Coats: tunica intima, tunica media & tunica adventitia.

* veins differ from arteries in the following (Peculiarities of veins):



- (1) they are larger than the corresponding arteries but with thinner walls (due to less muscular & elastic tissue in the tunica media).
- (2) veins increase in size gradually by receiving blood from smaller veins called tributaries while arteries become progressively smaller in size by giving branches.
- (3) The flow of blood is slow in veins & the venous pressure is much lower than the arterial pressure.
- (4) veins do not pulsate as arteries and therefore if a vein is opened, blood comes out in continuous stream while an opened artery ejects blood in spurts coinciding with the heart beats.
- (5) Many veins possess valves while arteries do not. The venous valves are folds of the tunica intima particularly in the veins of the limbs to prevent the back flow of blood inside the veins by gravity.
- (6) In the cadaver, veins appear bluish in colour & filled with clotted blood but arteries appear pink and empty.
- (7) large veins have dead space around them to allow for their distension during increased venous pressure.
 - (a) femoral vein lies alongside the femoral canal (dead space).
 - (b) pulmonary veins lie in the lower part of the hilum of lung where they can expand between the 2 lax layers of the pulmonary ligament.
- (8) large veins are not surrounded by thick fascia (unlike the arteries) e.g:
 - (a) axillary vein lies outside the fascial sheath surrounding the axillary a. & brachial plexus.
 - (b) the internal jugular vein has a thin part of carotid sheath around it.
 - (c) veins of the hand & foot lie mostly on the dorsum where deep fascia is thin.
- (9) Large veins are commonly accompanied by regional lymph nodes e.g
 - (a) Axillary vein has the lateral axillary lymph nodes alongside it.

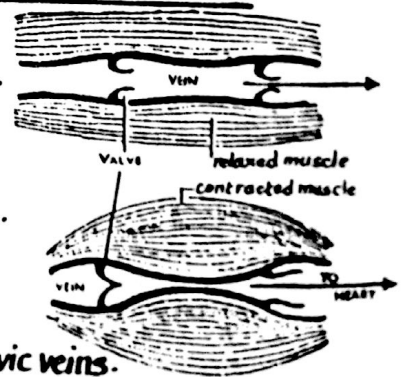


* Types of veins:

- (1) superficial veins: run superficial to the deep fascia, independent of arteries
- (2) deep veins: run deeply beneath the deep fascia & usually accompanied by arteries.

* Factors affecting the venous blood flow (venous return) in the deep veins

- (1) Contraction of the muscles surrounding the deep veins of the limbs (muscle pump or muscle milking action inside tight fascial compartment).
- (2) the venous valves which allow the flow of blood in one direction only (towards the heart) & prevent its back flow. Valves are numerous in the limb veins particularly the lower limb to counteract the effect of gravity.



N.B: there are veins lacking valves:

- (a) large veins as superior vena cava & inferior vena cava.
 - (b) portal vein and its tributaries (c) pulmonary veins (d) pelvic veins.
 - (e) cerebral veins & vertebral veins (f) dural sinuses
- (3) pulsations of the arteries surrounded by 2 venae comitantes are transmitted to these veins.



(4) the negative intra thoracic pressure helps to draw the venous blood towards the heart.

CONNECTIONS BETWEEN ARTERIES AND VEINS



Arteries and veins are connected together by the
 ↗ Capillaries
 ↘ sinusoids
 ↘ arteriovenous anastomosis

	1- Capillaries	2- Sinusoids
Nature	They are fine thin-walled permeable vessels connecting arterioles to venules to allow free exchange of materials between blood and tissues	
shape	<p style="text-align: center;">Capillaries</p>	<p style="text-align: center;">sinusoids</p>
Existance in the body	exist in all tissues & organs of the body except avascular structures e.g hyaline cartilage, cornea of the eye & epidermis of skin.	exist in certain organs only e.g : - liver, spleen - bone marrow - some endocrine glands
Lumen	narrow lumen having uniform diameter	wider but irregular in diameter.
Wall	single layer of endothelial cells with no pores, no phagocytic cells & no peri-vascular C.T.	single layer of endothelial cells having pores, phagocytic cells & peri-vascular C.T.

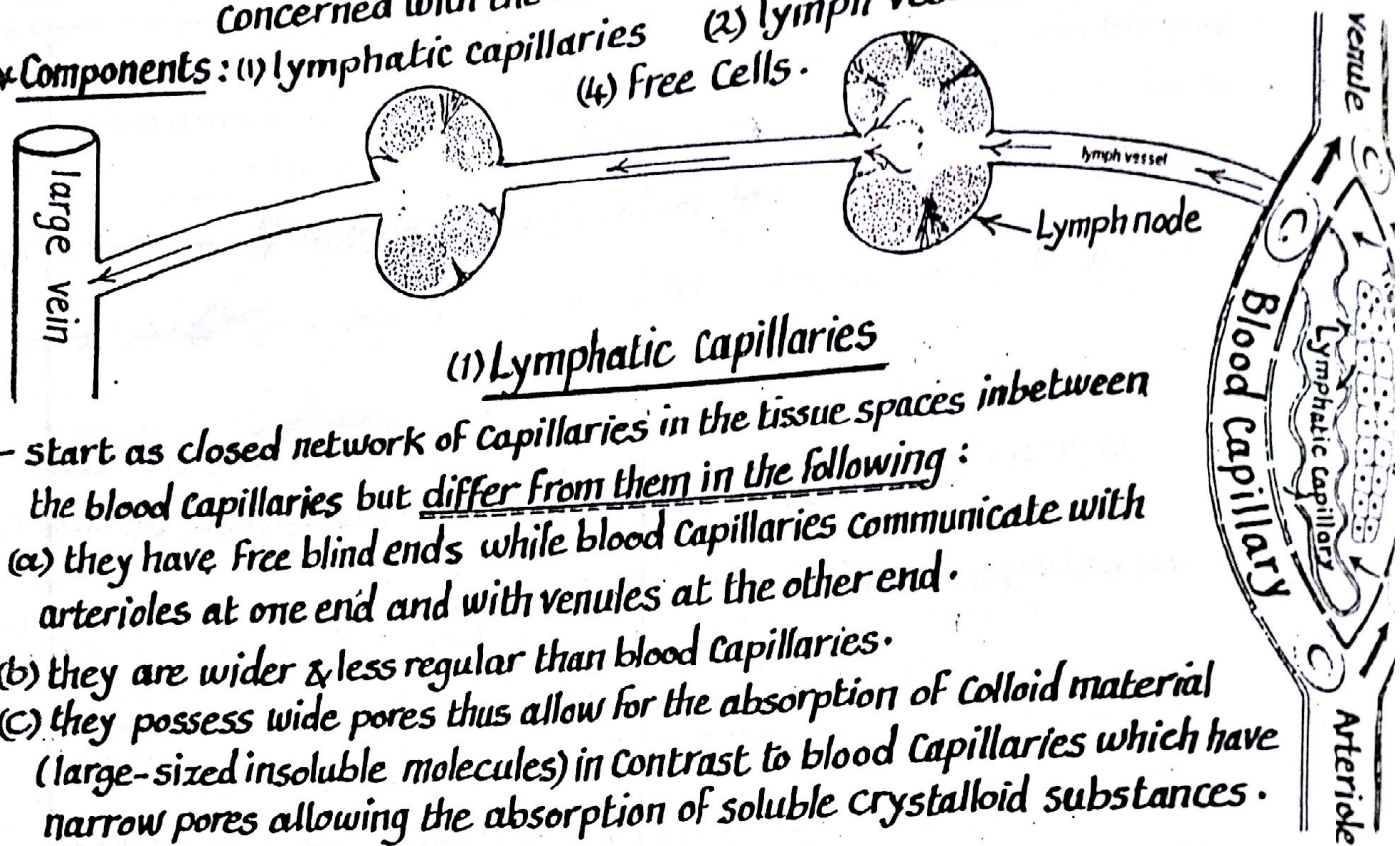
(3) Arteriovenous shunts (anastomoses):

- arterio-venous shunts are direct connections between arterioles & venules
- " " " allow blood to flow directly from arteries to veins without passing through the capillary bed. thus rising the venous blood pressure.
- these shunts are surrounded by smooth muscle sphincters (supplied by vasomotor sympathetic nerve fibres) & capable of complete closure.

* Sites of arteriovenous shunts:	* Significance (Function)
(1) in the dermis of skin (2) in the mucous membrane of nose (3) in the subcutaneous tissue of hand, foot, nose & lips.	regulation of body temperature: they open below 15° to increase the blood flow to the tissue thus rising its temperature. They also open above 40° to allow heat loss.
(4) in the submucosa of the intestine	the shunts close during absorption thus allowing the capillary bed to work (slowing the blood flow)
(5) in the erectile tissue of sex organs	to regulate erection.

* Definition: it is a Complementary Component to the Cardiovascular system & is concerned with the return of lymph (excess interstitial fluid) to the circulatory system.

* Components: (1) lymphatic capillaries (2) lymph vessels (3) lymph nodes (4) Free Cells.



(1) Lymphatic Capillaries

- start as closed network of capillaries in the tissue spaces in between the blood capillaries but differ from them in the following:

- (a) they have free blind ends while blood capillaries communicate with arterioles at one end and with venules at the other end.
- (b) they are wider & less regular than blood capillaries.
- (c) they possess wide pores thus allow for the absorption of colloid material (large-sized insoluble molecules) in contrast to blood capillaries which have narrow pores allowing the absorption of soluble crystalloid substances.

(2) Lymph Vessels

* Lymphatic Capillaries join to form larger trunks ($\frac{1}{2}$ to 1 mm in diameter) called lymph vessels.

* Course: superficial lymphatic vessels follow superficial veins while deep lymphatics tend to accompany arteries.

* Valves: lymph vessels contain many valves giving them a beaded appearance. The valves ensure the flow of lymph in one direction towards the large veins in the root of the neck.

* distribution: lymph vessels are present in all parts of the body except

- (1) the central nervous system where lymph is replaced by cerebro-spinal fluid
- (2) avascular structures as cartilage, cornea, epidermis, hairs & nails
- (3) Bone marrow (4) splenic pulp.

* Termination: lymph vessels traverse one or more groups of lymph nodes then unite to form larger vessels that finally open into large veins in the root of the neck.

(3) Lymph Nodes

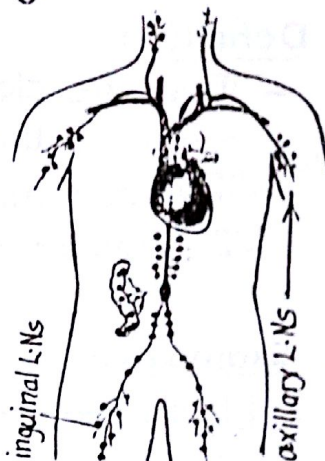
* They are small solid masses of lymphoid tissue (oval or kidney-shaped)

* they are usually present in groups situated in the course of lymphatic vessels

The groups of lymph vessels have definite anatomical sites e.g. at the root of the upper limb (axillary L.Ns) and the root of lower limb (inguinal L.Ns).

Lymph nodes have the following functions:

- (1) they act as filters for lymph: they contain macrophages which phagocytose the micro-organisms & the foreign materials in the lymph.
- (2) they are centres for lymphocyte production.
- (3) they are centres for building up the immune response as they are sites where interaction takes place between antigens and both the lymphocytes and macrophages.

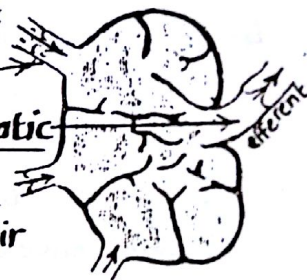


Circulation of lymph

The circulation begins in the tissue spaces where the excess tissue fluid transudes into the lymphatic capillaries & is now called lymph (clear colourless fluid rich in protein). Lymph then runs through lymphatic vessels which traverse one or more groups of lymph nodes which filter the lymph from micro-organisms & add lymphocytes to it.

The lymphatic vessels which enter the lymph node at its periphery are numerous vessels carrying lymph to the node & called afferent lymphatics while those emerging from the hilum are few or single & called efferent lymphatic.

At the root of the neck, lymphatic vessels from all the body collect forming 2 ducts (the thoracic duct & right lymphatic duct) which pour their lymph into the venous blood.



Factors affecting the flow of lymph

- (1) the filtration pressure in the tissue spaces forces the lymph into the lymphatic capillaries.
- (2) contraction of the surrounding muscles compress the lymph vessels
- (3) the arterial pulsations propels the lymph in the lymph vessels close to the artery.
- (4) the valves inside the L-vessels allow one way direction of lymph (towards root of the neck).
- (5) the negative intra thoracic pressure draws the lymph from abdomen to the thorax.

Functions of the lymphatic system

- (1) Absorption of excess interstitial fluid (lymph) & returning it to the circulation.
- (2) lymph nodes act as filters for the absorbed lymph (have phagocytic action against micro-organisms).
- (3) absorption of fat from the intestine.
- (4) production of lymphocytes & building up the immune response of the body.

• Definition :

- These are closed spaces lined by a thin membrane and contain a thin film of serous fluid for lubrication.
- They are invaginated by organs and tendons.
- They are also found at sites of friction between muscles & bones

• Examples :

1- Pleura :

serous sac which surrounds the lungs.

2- Pericardium :

serous sac which surrounds the heart.

3- Peritoneum :

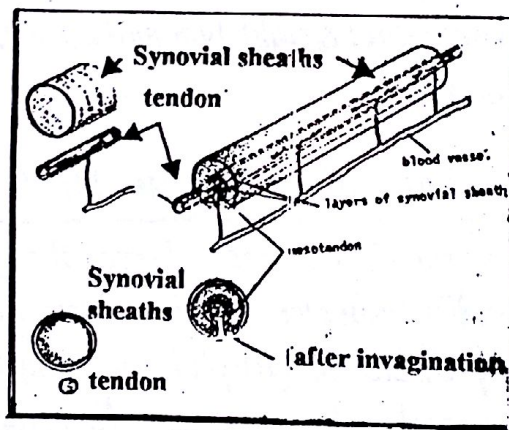
serous sac which surrounds the abdominal contents.

4- Tunica vaginalis :

serous sac which surrounds the testis.

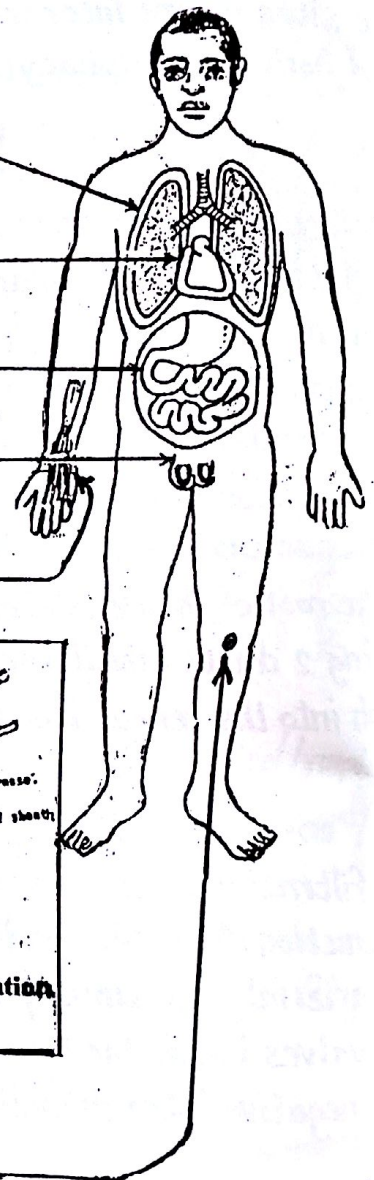
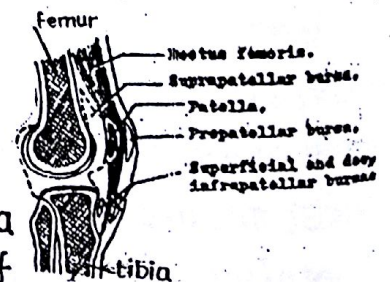
5- Synovial sheath :

- They are tubular serous sacs which envelop tendons as they pass under retinaculae
- The tendon invaginates the sheath from one side
- The tendon is attached to the sheath by a mesotendon which carry blood vessels to the tendon.



6- Synovial bursae :

- They are closed serous sacs which prevent friction between tendons of muscles and bone
- They are found in places where the skin or tendons rub against bone (and ligaments) e.g. prepatellar bursa
- Occasionally, the bursa communicates with the cavity of the joint e.g. Suprapatellar bursa communicate with knee joint



It is the system concerned with regulation, control and co-ordination of body functions.

Histological Structure of the N.S

1- Nerve cells (neurons)

Concerned with initiation & propagation of the nerve impulse

2 - supporting cells (neuroglia)

Concerned with the support and nutrition of the neurons

Structure of the neurone

The neurone is the structural unit of the nervous system. It consists of { cell body, dendrites, axon

(A) The **cell body** is characterized by having Nissl granules & neurofibrils in the cytoplasm

(B) The **dendrites** are short protoplasmic processes which carry impulses towards the cell body.

(C) The **axon** : is a single long process which carries the impulses from the cell body to the periphery.

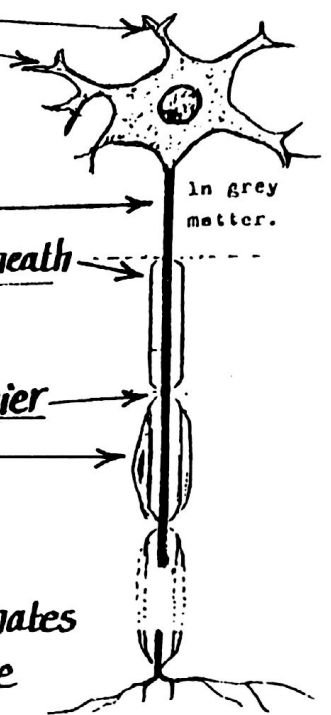
- In the grey matter of the C.N.S the axon has no sheath

- " " White " " " " " " " " " acquires a **myelin sheath** which acts as protective insulator to protect the axon & to speed up the flow of nerve impulses through the axon.

- the myelin sheath is absent at spaces called **Nodes of Ranvier**

- outside the C.N.S the myelin sheath acquires a **neurolemma** which is an outer sheath formed of Schwann's cells which nourish the axon, secrete myelin & essential for regeneration

(d) **Terminal endings** : the terminal branches of the axon which terminates by synapsing with the dendrites of another neurone or ends on the surface of a muscle fibre.

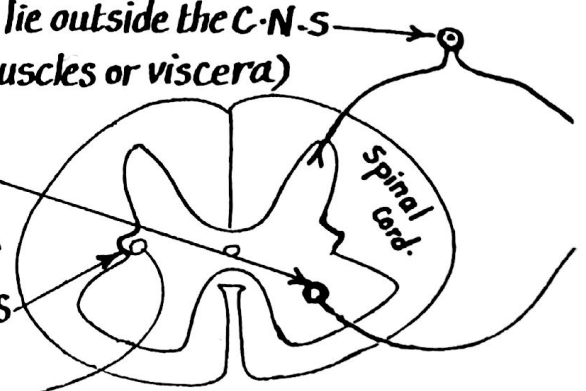


Functional types of neurones

(1) **Sensory or receptor neurones** : their cell bodies lie outside the C.N.S they carry impulses from receptors (in skin, joints, muscles or viscera) & conduct them to the C.N.S.

(2) **motor or effector neurones** : lie inside the C.N.S their axons carry motor impulses to activate muscles.

(3) **autonomic neurones** : their cell bodies lie inside the C.N.S their axons carry impulses to smooth muscles & glands.



ANATOMICAL SUBDIVISIONS OF N.S

peripheral nervous system (P.N.S)

* Consists of the cranial & spinal nerves & their associated ganglia
 (A) Cranial nerves (Cr. n.s) they are 12 pairs attached as follows

- (1) olfactory n. } attached to the cerebrum itself.
- (2) optic n. }
- (3) oculomotor n. } attached to the midbrain
- (4) trochlear n. }
- (5) trigeminal n. }
- (6) abducent n. }
- (7) facial nerve. }
- (8) auditory n. }
- (9) glossopharyngeal n. }
- (10) vagus nerve }
- (11) accessory nerve }
- (12) hypoglossal n. }

(B) the spinal nerves:

they are 31 pairs distributed as follows:

- 8 Cervical nerves : in the cervical region.
- 12 thoracic " : " " thoracic "
- 5 lumbar " : " " lumbar "
- 5 sacral " : " " Sacral "
- 1 Coccygeal nerve : " " Coccygeal "

central nervous system (C.N.S)

* Consists of the brain & spinal cord which lie in the central axis of the body protected by bone (skull & verteb. column)

* They contain cavities (ventricles of the brain & central canal of spinal cord) which are filled with cerebro-spinal fluid

* They are surrounded by 3 membranes called meninges:

- (1) dura mater : the outermost layer.
- (2) arachnoid " : the middle "
- (3) pia mater : the inner most layer.

* structurally, the C.N.S is formed of

(1) grey matter : consisting mainly of nerve cells.

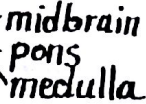(2) white matter : consisting of nerve fibres.

* parts of the brain:

(1) Cerebrum: formed of 2 hemispheres, each of which consists of several lobes.

(2) Cerebellum : below the posterior part of cerebrum.

(3) brain stem comprising 3 parts

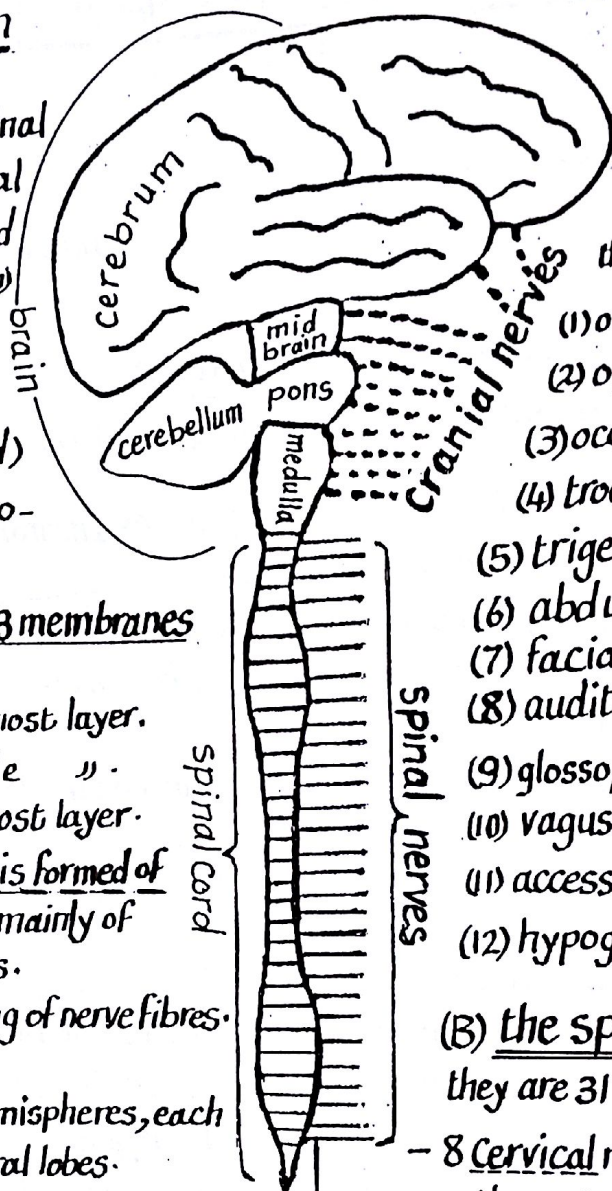


* Segments of the spinal cord:

the spinal cord has a segmental pattern being formed of the following segments (31):

- 8 Cervical segments - 12 thoracic segments
- 5 lumbar " - 5 sacral "
- one Coccygeal segment

N.B: each segment gives rise to pair of spinal nerves (right & left).



Ventricles of the brain & the Cerebrospinal Fluid (C.S.F)

* The C.S.F is the fluid circulates in the ventricles & central canals of the C.N.S & also fills the subarachnoid space.

* Production of the C.S.F:
the C.S.F is secreted by the choroid plexuses which invaginate the walls of the ventricles.

* Circulation of the C.S.F:
the C.S.F in each lateral ventricle → foramen of Monro

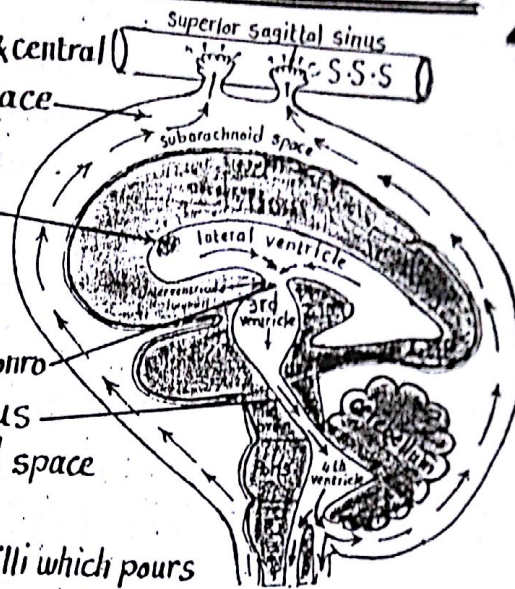
→ third ventricle → aqueduct of Sylvius

→ fourth ventricle → to the subarachnoid space

* Absorption:

the C.S.F is absorbed by means of arachnoid villi which pour the absorbed C.S.F into the dural venous sinuses particularly the superior sagittal sinus.

* N.B: if the C.S.F failed to be absorbed (due to thrombosis of the) it will accumulate in the ventricles of the brain leading to their distension & enlargement of the head (in children below 8 years), a condition called hydrocephalus



SPINAL CORD

* Shape: cylindrical Column 45 cm long

* Site: occupies the upper 2/3 of the vertebral canal

* Extent: it extends from the base of skull to the disc between the 1st & 2nd lumbar vertebrae.

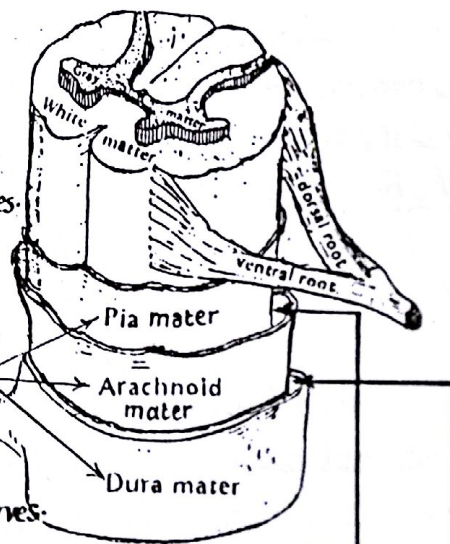
* Structure:

- (1) outer white matter formed of nerve fibres.
 - (2) inner H-shaped grey matter formed of nerve cells having:
 - (a) 2 posterior horns containing sensory cells
 - (b) 2 anterior horns containing motor cells
 - (c) a transverse grey commissure between the horns of both sides.
- * N.B: a lateral horn containing autonomic cells is present in certain regions of the spinal cord.

(3) a Central Canal extending longitudinally in the grey commissure.

* Coverings: the spinal cord is covered by 3 meninges called

* Segments: " " " " segmented into 31 segments: 8 cervical, 12 thoracic, 5 lumbar, 5 sacral & one coccygeal. Each segment gives off a pair of spinal nerves.



Meningeal Spaces

(1) Subarachnoid space: is the space between pia mater & arachnoid mater

- it contains C.S.F & blood vessels

(2) Subdural space: is a potential space between the dura mater & arachnoid mater

(3) Epidural space: " " " " " " " " & the bone:

(a) spinal epidural space: - between dura & vertebral periosteum.

- it contains venous plexuses, lymphatics & areolar C.T.

- it is a site for injection of local anaesthesia (nerve block).

(b) cranial " " :- between the periosteal & meningeal layers of dura.

- it contains meningeal arteries and veins.

AUTONOMIC NERVOUS SYSTEM (A.N.S) 42

- * Definition: it is the involuntary component of the nervous system.
- * Function: it is concerned with regulation of the activity of viscera, glands & smooth muscles i.e organs which are not under the control of will.
- * Control of the A.N.S: it is controlled by higher centres in the brain (mainly the hypothalamus).
- * Conduction of impulses from the C.N.S to the effector organ is carried by 2 neurones (preganglionic & postganglionic) with an autonomic ganglion between them.
- * Components: the A.N.S consists of 2 components (sympathetic & parasympathetic) which appear to be functionally antagonistic yet they are complementary.

A- SYMPATHETIC NERVOUS SYSTEM

(thoracodorsal or adrenergic system)

* Origin of preganglionic fibres:

it has a thoracolumbar origin: From the lateral horn cells of all thoracic segments & upper 2 or 3 lumbar segments of the spinal cord.

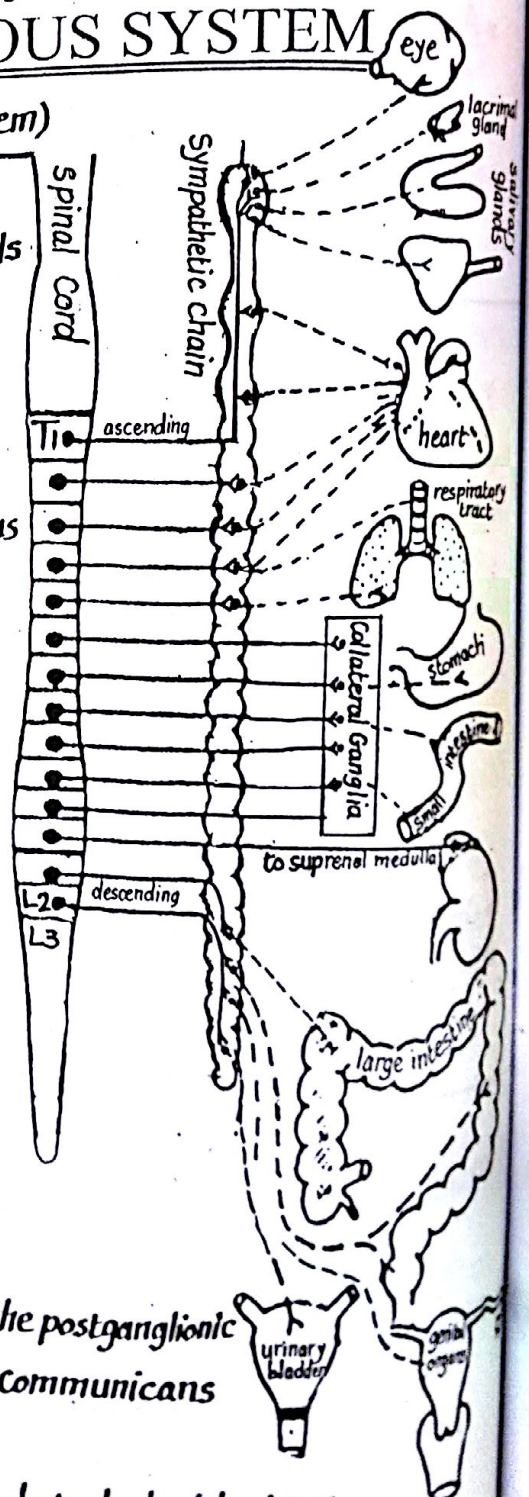
* Course & relay:

the preganglionic fibres leave the spinal cord via ventral root of spinal n. → main trunk of the nerve → ant. DV ramus of the nerve → leave the ant. ramus through the white ramus communicans (myelinated) to reach the corresponding ganglion of the sympathetic chain where they may have one of the following routes:

- (1) relay in the same ganglion they have entered
- (2) run up or down in the sympathetic chain to relay in a higher or lower ganglion in the chain.
- (3) leave the sympathetic chain without relaying where they reach autonomic plexuses in the thorax, abdomen and pelvis (cardiac, mesenteric & hypogastric plexuses) where they relay in collateral ganglia.
- (4) leave the sympathetic chain without relay to reach the suprarenal medulla where they relay there.

N.B: after relaying in the ganglia of the sympathetic chain, the postganglionic fibres pass to the nearest spinal nerve as grey ramus communicans (unmyelinated).

- * Function of the sympathetic N.S: it prepares the body to deal with stress conditions e.g fear, fight or flight. It is catabolic & energy consuming.



B- PARASYMPATHETIC NERVOUS SYSTEM 43

* Origin of preganglionic fibres:

- I- Cranial division:** from the nuclei of the cranial nerves number
- 3 (oculomotor nerve)
 - 7 (Facial nerve)
 - 9 (Glossopharyngeal n.)
 - 10 (Vagus nerve)

- II Sacral division:** from the lateral horn cells of the sacral segments number 2,3,4

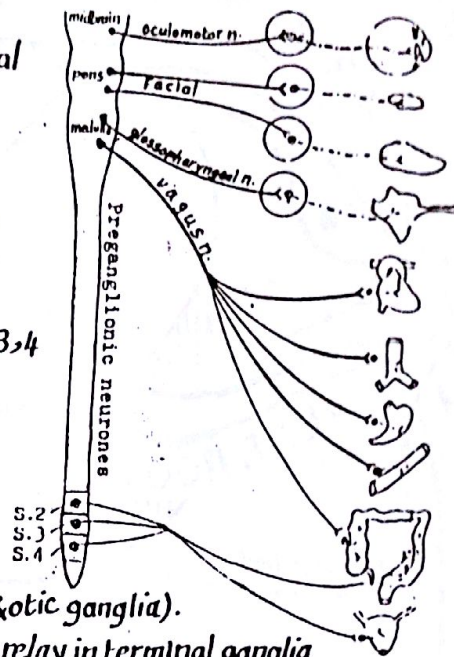
* Course & relay:

I- Cranial division:

- preganglionic fibres passing with the 3rd, 7th & 9th cranial nerves relay in one of the four parasympathetic ganglia of the head & neck (ciliary, sphenopalatine, submandibular & otic ganglia).
- preganglionic fibres passing with the vagus n. relay in terminal ganglia in the walls of the organs supplied.

- II- Sacral division:** the preganglionic fibres passing with the 2nd, 3rd & 4th sacral nerves relay in terminal ganglia in the walls of supplied organ

- * Function: it prepares the body systems to deal with normal functions occurring at rest & relaxation. It has anabolic & energy preserving activity.



structure	Sympathetic	Parasympathetic
Heart	- increase heart rate & contractility. - causes coronary dilatation.	- decrease heart rate & contractility. - causes coronary constriction.
Eye	- dilatation of pupil	- constriction of pupil - contraction of ciliary muscle.
Bronchi	- broncho-dilatation	- broncho-constriction.
Arteries	dilatation	no effect (not supplied).
supra renal medulla	secretion of adrenaline & noradrenaline	—
Liver	glycogenesis & gluconeogenesis	—
G.I.T	- contraction of sphincters - relaxation of smooth muscles	- relaxation of the sphincters - contraction of the smooth muscles

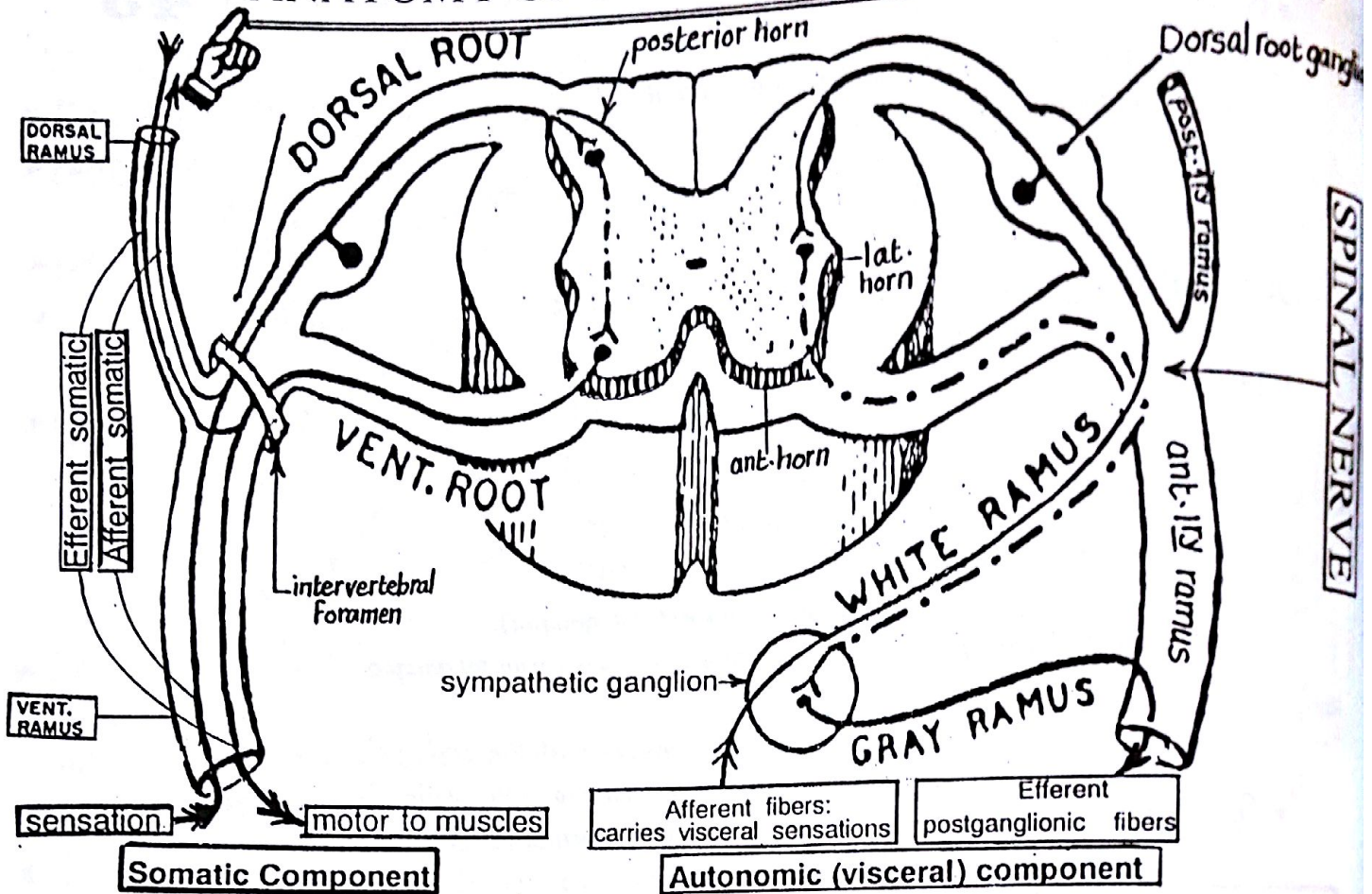
Referred Visceral Pain

- * Definition: it is a false reference of pain arising from a deep organ to an area of skin (dermatome) sharing the organ the same spinal cord segments.

- * Examples: (a) pain from the appendix is referred to the umbilicus because both share the same spinal cord segment of supply (T10).

- (b) pain from the heart (as in angina) is referred to the left pectoral region & left arm because both heart & skin share the same cord segments (T1-T5).

ANATOMY OF TYPICAL SPINAL NERVE



* There are 31 pairs of spinal nerves (8 cervical, 12 thoracic, 5 lumbar, 5 sacral & 1 coccygeal).

* Each spinal n. arises from the spinal cord by 2 roots (dorsal & ventral) as follows:

- (1) Dorsal root: - Consists of sensory fibres carrying sensations from skin, joints, bones & muscles to the sensory cells of the posterior horn of the spinal cord
- it has a dorsal root ganglion (consisting of sensory neurones) attached to it.
- (2) Ventral root: - Consists of motor fibres which are the axons of the anterior horn cells.
- in certain regions of the spinal cord it also carries preganglionic autonomic fibres which are the axons of the lateral horn cells.

* The trunk of the spinal nerve: is formed by the union of the dorsal & ventral roots
- it is a very short mixed n. (containing motor, sensory & sometimes autonomic fibres).
- it emerges from the intervertebral foramen & divides immediately into 2 primary rami.

* Rami

(a) anterior primary ramus:

- it is larger & longer than the posterior PR ramus.
- it runs laterally & anteriorly in the body and may communicate with other rami to form plexuses.
- a sympathetic ganglion is attached to it by 2 rami communicans $\left\{ \begin{array}{l} \text{white ramus (myelinated)} \\ \text{grey ramus (non-myelinated)} \end{array} \right.$

(b) Posterior primary ramus:

- it is smaller & shorter than the anterior PR ramus.
- it runs backwards to supply the muscles & skin of the back
- it always runs singly (does not share in plexuses) & has no sympathetic ganglion attached to it.

N.B: the anterior 1st rami join together forming plexuses as follows:

(1) Cervical plexus: formed in the neck by the upper 4 cervical nerves.

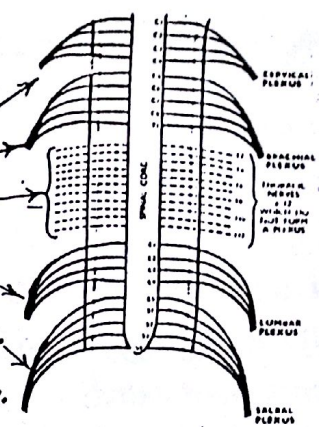
(2) Brachial plexus: " " " " " by the lower 4 cervical & 1st thoracic n.

N.B: thoracic nerves (except the 1st do not form plexuses but run singly

(3) Lumbar plexus: formed in the abdomen by the upper 4 lumbar nerves.

(4) Sacral plexus: formed in the pelvis by the lower 2 lumbar & upper 2 sacral ns.

(5) Coccygeal plexus: " " " " " lower 2 sacral & 1st Coccygeal nerve.



Components of a spinal nerve



* Each typical spinal n. is mixed i.e. Containing both somatic & autonomic components:

(A) Somatic Component: Consisting of two types of fibres:

(1) Afferent (sensory) somatic fibres: carry sensations from the skin & pass through the dorsal (sensory) root of the spinal n. → posterior horn of the spinal cord.

(2) Efferent (motor) somatic fibres: are axons of A.H.Cs. They pass through the anterior (motor) root → spinal n. → to both rami. They carry motor impulses to skeletal muscles.

(B) Autonomic (Visceral) Component: Consisting of the following types of fibres:

(1) Afferent (sensory) fibres: carry visceral sensations from viscera → reach the sympathetic chain → white ramus communicans → spinal n. → posterior root → spinal cord.

(2) Efferent preganglionic fibres: are axons of lateral horn cells (in all thoracic & upper 2 lumbar segments). They pass with the ventral (motor) root → spinal nerve → the ventral ramus → white ramus → ganglion of symp. chain to relay.

(3) Efferent postganglionic fibres: arise from the sympathetic ganglion. Some fibres reach the anterior 1st ramus through the grey ramus communicans while other fibres continue in the sympathetic chain.

N.B: (1) the white ramus communicans contains both Efferent preganglionic symp. fibres & Afferent symp. fibres
 (2) grey " " " only efferent postganglionic symp. fibres.

Difference between spinal nerves & cranial nerves

	Spinal nerves (31)	Cranial nerves (12)
Attachment	-each nerve is attached to the spinal cord by 2 roots: ventral & dorsal	-each cranial nerve is attached directly to the brain
Arrangement	-all spinal nerves are attached in a regular manner to the sides of the spinal cord.	-attached irregularly to the front, sides or back of the brain.
Ganglia	-all spinal nerves have dorsal root ganglia	-some cranial nerves possess one or 2 ganglia while other nerve have no ganglia
Type of fibres	-all spinal nerves are mixed (contain motor & sensory fibres)	-Some nerves are mixed while other are either purely sensory or purely motor

Segmental innervation of the skin

* Important remarks:

* the skin of the body is divided into series of strips called dermatomes.



* A Dermatome: is the area of skin supplied by the sensory fibres of a single spinal nerve.

* In the trunk, dermatomes lie in orderly numerical sequence from above downwards.

* In the limbs, the dermatomes are first arranged in the embryo in numerical sequence but as the limbs grow, the central dermatomes are pulled in such a way that they are represented in the distal part of the limb & buried (disappear) proximally along the axial line of the limb both ventrally & dorsally.



* The Axial line is defined as the line along which central dermatomes are missing i.e. it is the line of junction of dermatomes supplied from discontinuous spinal segments. For example

(A) In the upper limb:

(1) the anterior axial line extends from the sternal angle to the front of the limb down to the wrist.

(2) the posterior axial line extends from the 7th cervical spine across the back of the arm down to the insertion of deltoid.

(B) In the lower limb:


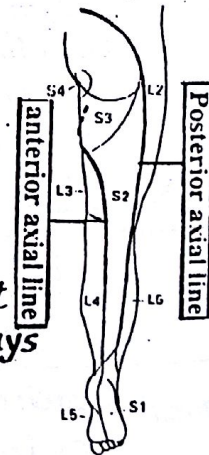
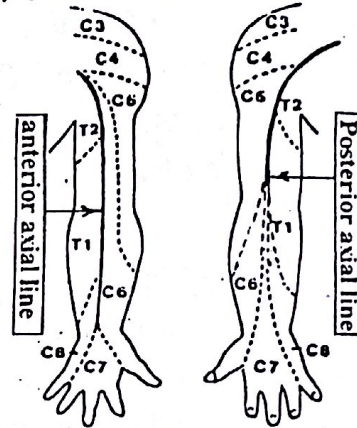
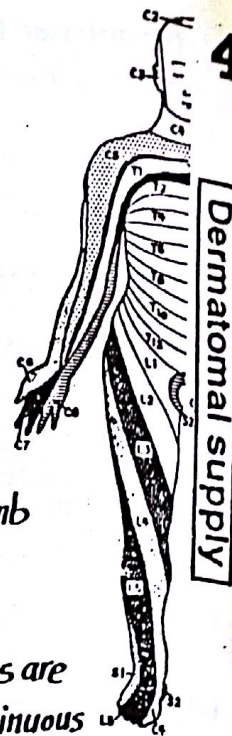
(1) the anterior axial line: extends in a spiral manner from the root of the penis to the back of thigh & back of leg down to the heel.

(2) the posterior axial line: extends from the lower border of L4 vertebra to the back of thigh down to the head of fibula and then to the middle of the calf.

* Overlapping of dermatomes:

there is varying degree of overlapping of adjoining dermatomes, so that the area of sensory loss following damage of spinal cord segment is always less than its dermatomal distribution.

N.B: overlapping of dermatomes never occur across axial lines.



Segmental innervation of muscles

* Myotome: is the portion of the muscle which is supplied by one segment of spinal cord.

* most of skeletal muscles are supplied by 2 successive segments of spinal cord, however, few muscles are unisegmental or trisegmental

* muscles having common IRV action on a joint are supplied by the same spinal cord segments

* the opposing group of muscles to the previous are also supplied by spinal segments which follow in numerical sequence e.g. flexor muscles of the elbow are supplied by C5, 6 while their opposing extensors are supplied by C7, 8.

A

abdomen	البطن	anisotropic	متباين الخواص
abduction	حركة التباعد	ankle joint	مفصل الكعب
absorption	امتصاص	antagonist	معارض، مضاد
abortion	اجهاض	anterior	امامى
abundant	وفير	antibodies	اجسام مضادة
accessory	تكميلى	aneurysm	انتفاخ شريانى
accomodate	يستوعب - يكيف	anus	فتحة الشرج
acetabulum	حُق الفخذ (تجويف مفصلى فى عظم الحوض)	aperature	فتحة
acoustic	سمعى	apex	قمة
activity	نشاط - فاعلية	aponeurosis	وتر مفلطح
adapt	يتلاءم - يطوع	apparatus	جهاز
additional	اضافى	appendages	زوائد
adduction	حركة التقريب	appendicular	طرفى
adipose	دهنى	appendix	الزائدة الدودية
admixture	مزيج	applied	تطبيقى
adolescence	مرحلة المراهقة	approach	مدخل
adolescent	مراهق	appropriate	مناسب
adulthood	مرحلة البلوغ	approximation	تقريب
adventitia	الطبقة الخارجية للوعاء الدموى	arachnoid	عنكبوتى
afferent	مورد الى	arch	قوس
afford	يطبق	areolar	ذو فجوات
ageing	كبر السن	arrangement	ترتيب
albinism	مرض ابيضاض الجلد	arteriole	شريان صغير
albumin	زلال البيض	artery	شريان
alimentary tract	القناة الهضمية	arthrology	علم المفاصل
alternative	بديل	articular	مفصلى
alveoli	حويصلات	ascending	صاعد
anabolic	بنائى للأسجة	aspects	نواحي - اوجه
anastomosis	انفتاح الأوعية على بعضها	atlas vertebra	الغقرة العنقية الأولى
angina pectoris	الذبحة الصدرية	atrium	أذين القلب
angular	ذو زوايا	atrophy	ضمور - تآكل
		attachment	اتصال

atypical	غير نموذجي	canaliculi	قنوات دقيقة
auditory	سمعي	cancellous	اسفنجي
auricle of the ear	صوان الأذن	capillaries	شعيرات
avascular	خالي من الأوعية الدموية	capsule	حافطة المفصل أو للعضو
axial	محوري	cardiac	شبه للقلب
axilla	ابط	cardiovascular	قلبي وعائي
axis	محور	carpal	خاص برسغ اليد
B		cartilage	مضروف
ball and socket	الكرة والحق	categories	فئات
barrier	حاجز	cavity	تجويف
base	قاعدة	cells	خلايا
basis	أساس	cerebellum	المخيخ
belly	بطن العضلة	cerebrum	المخ
bend	ثنية	cervical	عنقي
biaxial	ثنائي المحور	cessation	توقف
blind	ذو نهاية مسدودة - اعمى	chewing	مضغ
bones	العظام	chondrification	تكوين غضاريف
border	حافة ، حرف	child birth	ولادة الطفل
boundaries	حدود	cilia	اهداب
brachial	عضدي	circumduction	حركة الدوران
brain	المخ - الدماغ	circumference	محيط
brevis	قصير	clavicle	عظم الترقوة
bronchi	الشعب الهوائية	classical	تقليدي
bundle	حزمة من الألياف	cleavage	انشطار
bursa	كيس زلالي	clinical	الكلينيكي
buttock	الريف	clitoris	البظر
C		coccygeal	خاص بعظم العمص
cadaver	جثة مخصصة للتشريح	collapse	ينهار - يعلق - يتدهور
calcification	ترسيب الكالسيوم	collar	ياقة الرقبة
calf of leg	بطن (سمانة) الساق	collateral	جانبي
calibre	قطر الأنبوبة أو الوعاء	collection	تجمع
		column	عمود
		columnar	عمودي

components	مكونات
compress	يضغط ، يكبس
compression	ضغط
concave	مقعر
concentric	حلقى
concentration	تركيز
condensed	مكثف
cone-shaped	مخروطى الشكل
conical	مخروطى
connective tissue	النسيج الليفى
consequently	وبالتالى ، وبناء على ذلك
considerable	كثير
conspicuous	واضح
constriction	اختناق ، ضيق
construct	يشيد ، يبنى
content	محتوى
contract	ينقبض
contraction	انقباض
contracture	انقباض لا يتبعه ارتخاء بسبب التليف
contralateral	الجانب المقابل
contrast	تضاد ، تباين
coordination	تنظيم ، تنسيق
cornea	قرنية العين
cortex	القشرة الخارجية
costal	خاص بالاضلاع
counteract	يقاوم ، يبطل مفعول
course	مجرى ، مسار
combat	يحارب ، يقاوم
comitantes	مرافق ، مصاحب
commisure	وصلة عرضية بين الجانبين
compact	مصمت ، متماسك
cranial	خاص بالجمجمة
crease	حز (شنية) بالجلد
crest	حرف بارز ، عرف

criteria	معايير
cruciate	على شكل صليب
cuboidal	مكعب الشكل
cushion	بروز على شكل وسادة
cylindrical	اسطوانى

D

decline	انحدار ، تناؤل ، تدهور
deep	عميق
defence	دفاع
deficient	ناقص
definition	تعريف
deformed	مشوه
delicate	رقيق
demonstrate	يبين ، يوضح
denervated	منزوع العصب
dense	مكثف
deposit	يرسب ، راسب
depression	منخفض
deprive	يحرم
derive	يشق
dermis	أدمة الجلد
descending	نازل ، متجه الى اسفل
desiccation	تجفيف
detect	يكشف ، يبين
deterioration	تدهور
determine	يحدد
develop	ينمو
devoid of	خال من
diaphysis	ساق العظمة قبل تمام الاتمام مع نهايتها
diastole	ارتخاء القلب
differentiation	تمييز
diffusion	انتشار
digits	اصابع

diminish	يتناقص	ensure	يضمن
diminution	تناقص	envelop	يحيط الشيء بجلاف
distal	ناحية الطرف، بعيداً عن الجذع	environment	البيئة أو الوسط المحيط
distribution	توزيع	epidermis	بشرة الجلد
disuse	سوء استعمال	epiglottis	لسان المزمار
dorsiflexion	انشاء القدم الى الأعلى	epiphysis	نهاية العظمة الطويلة قبل الالتحام
drag	يجر، يسحب	epithelium	السيج الطلاقي
duct	قناة	equivalent	مكافئ
dura mater	الأم الجافية المحيطة بالمدخ	erect	منتصب
dwarf	قزم	erosion	تآكل، نخر
		evaporation	تبخر
		eversion	حركة اتجاه أخمص القدم الى الخارج

E

ectoderm	الطبقة الخارجية للجنين	evident	واضح
effective	فعال، مؤثر	exception	استثناء
efferent	وعاء أو عصب خارج	exchange	تبادل
efficiency	كفاءة، مقدرة	excitability	القدرة على الإثارة والتنبية
eject	يقذف	exist	يحدث، يوجد
elastic	مطاط	exocrine glands	الغدد ذات القنوات
elbow joint	مفصل الكوع	expand	يتوسع، يتقدم
elevation	رفع	expansile	ذوقرة على التمدد
elicit	يظهر، يحدث، يبين	expose	يكشف، يظهر
eliminate	يلغى، يتخلص	extension	حركة الفرد أو البسط
ellipsoid	بيضاوي	external	خارجي
embedded	مطهور، مدفون	extra ocular	خارج مقلة العين
embryology	علم الأجنة		
eminence	بروز، ارتفاع		
emphysema	مرض انتفاخ حويصلات الرئة		
encircle	يحيط ب، يطوق		
endings	نهايات		
endocrine glands	الغدد الصماء		
endometrium	العشاء المبطن للرحم		
endoscopy	الفحص بالمنظار		
engulf	يلتهم		
ensheath	يغلف		

F

facet	سطح مفصلي ناعم
facial	خاص بالوجه
facilitate	يسهل
factors	عوامل
fascia	الطبقة الرخوة الليغية
fasciculi	تحت الجلد مباشرة أو حول العضلات
	حزيمات من الألياف

fatigue	اجهاد ، تعب
features	صفات
female	انثى
femur	عظم الفخذ
fenestrations	ثقوب
fertilization	احصاب
fibre	ليف
fibril	ليفنة دقيقة
Fibrosis	تليف
Fibrous	ليفى
Fibula	عظم الشظية
filter	مرشح
finger prints	بصمات الاصابع
fissure	شق أو فلق
fix	يثبت
flat	مسطح
flava	اصفر اللون
flexible	قابل للثناء
flexion	انشاء المفصل
flexure	طيه ، انحناء
foetus	جنين
follicle	حوصلة
foramen	ثقب
Fossa	انخفاض على السطح
fragile	هش
Fragmentation	تفتيت
Framework	هيكل
Friction	احتكاك
Frontal	جبهى
function	وظيفة
Furrow	مجرى
Fusion	التحام
fusiform	مغزلى الشكل

G

gall bladder	الحوصلة المرارية
gastric	متعلق بالمعدة
genetic	وراث ، متعلق بالمجينات
gland	عدة
glans penis	مقدمة القضيب عند الذكر
globular	كروى الشكل
glomeruli	كبيبات الكلية
goblet cells	خلايا مخاطية لها شكل الكأس
granules	حبيبات
gravidarum	خاص بالحمل
grey matter	المادة الرمادية فى المخ
groove	أخدود ، مجرى
gross	يرى بالعين المجردة
growth	نمو

H

haemopoiesis	انتاج خلايا الدم
hamulus	خطاف
hang	يعلق
hard	صلب
hiatus	فتحة
hilum	مدخل العضو
hinge	مفصل الباب
homogenous	متجانس
horizontal	افقى
horn	قرن
hyaline	شفاف
hyoid bone	العظم اللامى (احد عظام الرقبة)

I

idiopathic	غير معلوم السبب
immature	غير ناضج
immunity	مناعة

impair	يعرقل
impede	يعيق
Impermeable	غير منفذ
incision	شق جراحي
individual	فرد
infection	عدوى
inferior	سفلى
information	معلومات
ingest	يبتلع
initiate	يبدأ
injurious	ضار
injury	إصابة
Innervate	يغذى بالأعصاب
inspection	الفحص بالنظر
insulator	عازل
intact	سليم
interaction	تفاعل
intercalated	محشور بين
intercellular	بين الخلايا
interest	اهتمام
interference	تداخل
interlacement	تشابك
intermediate	وسطى
intermittent	على صورة متقطعة (ليست منتظمة)
inter muscular	بين العضلات
Internal	داخلي
interosseous	بين العظام
Interstitial	بين الخلايا
intervene	يتدخل ، يتوسط
intestine	الأمعاء
Intima	بطانة الوعاء الدموي
Intracapsular	داخل حافظة المفصل
intracartilagenous	داخل الغضروف
intramembranous	داخل الغشاء

intrauterine	داخل الرحم
invade	يهاجم
invaginate	يدفع جدار التجويف من الخارج الى الداخل
invasion	مجموع
inversion	قلب أخص القدم الى الداخل
ipsilateral	على نفس الناحية
irids	حدقة العين
irregular	غير منتظم
ischaemia	حرمان العضو من التغذية بالدم
ivory	عاج

J

Jaundice	اصفرار الجلد والعينين
Joints	مفاصل
Jugular	ودجى

K

Kidney	كلية
Knee	ركبة
Knuckles	بروز رؤوس عظام مشط اليد

L

labia	شفاه
labium	شفة
labrum	حرف
lack	فقدان
lacteal	خاص باللبن
lacuna	فجوة ، ثغرة
lamella	طبقة
lamellated	على هيئة طبقات
lamina	صفحة
land marks	علامات ، معالم
larynx	حنجرة

lateral layer	متجه الى الخارج طبقة	media	الطبقة العضلية في جدار الوعاء الدموي
lax	مرتخي	medial	اقرب الى الخط المنصف للجسم
lash	حزمة	median	الخط المنصف للجسم
lessen	يقلل	medicolegal	خاص بالطب الشرعي
lever	رافعة	medium	متوسط - وسط
liberation	تحرير ، اطلاق سراح	medulla oblongata	النخاع المستطيل
ligament	رباط	medullary cavity	التجويف النخاعي
lineae	خطوط	membrane	غشاء
linear	خطي (على شكل خط)	meninges	أغشية المخ
lingual	خاص باللسان	menstruation	الدورة الشهرية
lip	شفة	menisci	اقراص غضروفية هلالية الشكل
liver	كبد	mental	خاص بالعقل
localized	محدد	mesentery	المساريقا
located	يوجد في	meshes	فراغات بين اجزاء الشبيج
locked	متربس	meshwork	شبيج شبكي به فراغات
locomotion	حركة	mesoderm	الشيح الأوسط للجنين
lodge	يحتوي ، يأوي بداخله	metacarpal bones	امشاط اصابع اليد
longitudinal	طولي	metatarsal bones	امشاط اصابع القدم
loop	عروة	microorganisms	ميكروبات
lubricate	يشحم	microscopic	مجهرى
lumbar	قطني ، خاص بالمنطقة القطنية	midbrain	المخ المتوسط
lumen	تجويف	minimum	الحد الأدنى
lunule	الهلال الأبيض عند جذر الظفر	mitotic division	الانقسام الانشطاري
lymph	السائل الليمفاوي	mobile	متحرك
lymphatics	الوعية الليمفاوية	mobilization	تحريك

M

macrophage	خلية آكله كبيرة الحجم	moisten	يرطب
male	ذكر	movement	حركة
manifest	توضح	mucous	مخاطي
marrow	نخاع	mucus	مخاط
matrix	ارضية الشبيج أو العَضو	multiaxial	متعدد المحاور
mature	ناضج	multiplication	تكاثر في العدد
maximum	الحد الأقصى	muscular	عضلي
		myocardium	عضلة القلب

N			
naked	عاري	osteoblast	خلية مكونة للعظام
necrosis	تآكل، تحلل	osteoclast	خلية آكله للعظام
neoplasm	ورم	osteocyte	خلية عظمية ناضجة
nerves	اعصاب	osteomyelitis	التهاب العظام التقيحي
nests	اعشاش	overlie	يغطي
neurogenic	ذو منشأ عصبي	ovoid	بيضاوي
nipple	حلمة الثدي	P	
node	عقدة	pace maker	ضابط لنبضات القلب
nodule	عقدة صغيرة	pad of fat	حشوة من الدهون
normal	طبيعي	palm	راحة اليد
notch	حز	palpation	الفحص باللمس
nourishment	تغذية	papillae	حلمات
nutrient	غذاء	papillary	على شكل حلمات
nutrition	تغذية	paralysis	شلل
O		parietal	جداري
oblique	مائل	particular	شيء بعينه
obliteration	انسداد	patella	عظم الرضفة
occlusion	انسداد	pathological	مرضى
occur	يحدث	pelvis	حوض
oedema	تورم بسبب احتجاز السوائل	penetrate	يخترق
oesophagus	المريء	penis	قضيب الذكر
ointment	مرهم	pennate	على هيئة ريشة الطائر
olfactory	خاص بالشم	percussion	الفحص عن طريق النقر بالأصابع
opaque	معتم	perforation	ثقب
operation	عملية	perform	يؤدي
optic	بصري	periosteum	الغشاء المحيط بالعظم
organs	اعضاء	peristalsis	الحركة الودية للأمعاء
orifice	فتحة	peritoneum	الغشاء البريتوني
ossicles	عظيمات	perpendicular	عمودي
ossification	تكوين العظام (تعظم)	phagocytosis	التهام
osteoarthritis	التهاب المفاصل	phalanges	سلاميات الأصابع
		phase	مرحلة، وجه من الوجوه

pia mater	الأم المحنون المحيطة بالمخ
pigmentation	تلون
pinna of ear	صوان الأذن
pivot	محور ارتكاز
placenta	المشيمة
plain	بدون خطوط (ساده)
plane	مستوى
plantar	خاص بأخمص القدم (السطح السفلى)
plate	صفيحة ، لوح
plentiful	وفير
pleura	الغشاء البللورى
plexus	شبكة - صفيحة
polygonal	متعدد الجوانب
pens	البريخ
pores	فتحات
portal	بوابى
possess	يملك
posterior	خلفى
postural	خاص بوضع الجسم
practically	عملياً
precise	دقيق
predominant	غالب ، شائع
prevalent	شائع
primitive	بدائى ، اولى
procedure	طريقة العمل
process	عملية - نتوء
production	انتاج
projection	بروز
prolonged	ممتد
prominent	بارز ، واضح
pronation	حركة الكعب وهى خاصة باليد
properties	خواص
proportion	نسبة
proximal	قريب من الجذع

puberty	مرحلة البلوغ
pulmonary	خاص بالرئتين
pump	مضخة

Q

quadrangular	مربع
quadrilateral	مربع
quiescent	ساكن ، هامد

R

radiography	التصوير بالأشعة
radius	مظمر الكعبرة
ramify	يتفرع
ramus	فرع
raphe	خط ليفى بين العضلات
receptor	مستقبل الاحساس
recoil	ارتداد
record	يسجل
rectus	مستقيم الشكل
referred pain	الآلم المحسوس بعيداً عن مصدره
reflex	منعكس
regeneration	تجديد الخلايا
region	منطقة
regulate	ينظم
regurgitation	ارتجاع
reinforce	يدعم
remodelling	اعاده التشكيل الى حالته الاصلية
repair	ترميم
repeatedly	متكرر
requirements	احتياجات
resemble	يشبه
reservoir	مستودع
resilient	مرن
resistance	مقاومة

respectively	على التوالي
respiratory	تنفسي
retina	شبكة العين
retinaculum	رباط ممتد فوق اوتار العضلات كالقيد
retraction	انكماش
reverse	العكس
rheumatic	روماتيزمي
rheumatoid	روماتويد
rhythm	ايقاع
ribs	اضلاع
ridge	حرف
rigid	متصلب
rotation	دوران
rotatory	دائري

S

sacral	عجزي
saddle	سرج الحصان
scale	قشرة
scanty	قليل
scar	ندبة التهام الجرح
scrotum	كيس الخصية
sebaceous	دهني
secretion	افراز
seller	مشابه للسرج
semilunar	هلالى الشكل
sensitive	حساس
sensory	حسي
septum	حاجز
serous	مصلي
sesamoid	سمسمي
sex	جنس

sheath	غلاف
shedding	تساقط
shoulder	الكتف
shunt	وصلة جانبية
significance	أهمية ، مغزى
sinus	جيب
sinusoids	على شكل جيوب
skull	جبهة
sliding	انزلاقي
soak	ينقع
socket	تجويف
sole of foot	احمص القدم
sperm	حيوان منوى
sphincter	صمام
spindle	مغزل
spine	شوكة
spiral	لولب
spleen	طحال
spongy	اسفنجي
spontaneous	تلقائي
squamous	قشري
stability	ثبات
sternum	عظم القص
stiffening	تصلب ، تخشب
stimulus	مؤثر ، منبه
stomach	المعدة
strap	شريط
stratified	ذو طبقات
stress	اجهاد
striated	مخطط
striations	خطوط
subdivisions	اقسام
subjected to	معرض لـ
subsidiary	فرعى

sulcus	مجرى	toe	اصبع القدم
superficial	سطحي	tonsil	لوزة الحلق
superior	علوي	torsion	التواء
supination	حركة بسط اليد	toxin	سم
supply	امداد	trabeculae	حواجز صغيرة
support	دعم	trachea	القصبة الهوائية
suppression	اخماد	transitional	انتقالي
surface	سطح	translucent	شفاف
surgical	جراحي	transmission	نقل
sweatglands	الغدد العرقية	tributaries	روافد
symmetrical	متماثل على الجانبين	trochanter	بروز كبير
symphysis	ارتفاق	trochlea	بكرة
syncytium	شبكة ذواتويه متعددة	tube	انبوبة
syndesmosis	التحام ليفي	tubercle	بروز صغير
synovial	زلالي	tuberosity	بروز أكبر
systematic	منهجي	tunica	طبقة ، غلاف
systemic	حسب الأجهزة		

T

tarsus	رسغ القدم
tearing	تمزيق
temporary	موقت
tendency	ميل
tendon	وتر العضلة
tension	توتر - شد
terminal	نهائي
testis	خصية
texture	بنية النسيج
thermal	حراري
thoracic	صدرى
thumb	اصبع الإبهام
thymus	الغده التيموسية
tibia	عظم قصبة الساق
tissue	نسيج

U

ulna	عظم الزند
ultraviolet	الأشعة فوق البنفسجية
umbilicus	السره
underlying	يقع تحت
undulations	تقوجات
uniaxial	وحيد المحور
uniform	متسق
ureter	المحالب
urinary	بولي
urogenital	خاص بالبول والتناسل
uterus	الرحم

V

valve	صمام
variations	اختلافات
vascular	وعائي

vasoconstriction	انقباض الوعاء
vasodilatation	انتشاع الوعاء
vein	وريد
ventricle	بطين
venule	وريد صغير
vermiform appendix	الزائدة الدودية
vertebral column	العمود الفقري
vertical	عمودي، رأسي
vessel	وعاء
via	عن طريق
viscera	أحشاء
visceral layer	الطبقة الحشوية
visible	مرئي
vital	حيوي
voluntary	ارادي
vulnerable	معرض للاصابة

W

wavy	متقوِّج
wearing off	تآكل
withstand	يتحمل
wound	جرح
wrinkled	مجعد

X

X-ray	الأشعة السينية
xiphoid	خنجري

Y

yolk	مح
------	----

Z

zona pellucida	المنطقة الشفافة المحيطة بالبيضة الناضجة
zygo-zygote	وصلة أو التحام أو اندماج البويضة المخصبة أو الملقحة

Prefixes and Suffixes

A

a-, ab-	away from, away
ad-, an-	without, lack, not
ad-	to, toward
adeno-	gland
adip-	fat
af-	to
-algia	pain
alve-	trough, channel, cavity
amyl-	starch
angl-	vessel
ante-	before
anti-	against
apo-	away from, detached
arach-	spider
arthro-	joint
-ase	enzyme
auto-	self

B

bi-	two
blast-	bud, germ
brachi-	arm
brachy-	short
brady-	slow

C

calc-	heel, limestone
carbo-	coal, charcoal
cardi-	heart
cephal-	head
cerebro-	brain
chole-	bile
chondr-	cartilage
chromo-	color
circum-	around
-cle	small
con-	with, together
contra-	opposed, against
cortic-	rind, bark
costo-	rib
cuti-	skin
cyst-	bladder
cyt-	cell

D

de-	remove, decrease
derm-	skin
di-	two
dia-	through, between
dis-	denoting separation
dys-	bad, difficult

E

ecto-	on outside
ef-	out of
-emia	blood
endo-	within
entero-	intestine
epi-	upon, above
erythro-	red
eu-	good, well
ex-	out, away from

F

fasc-	band
-ferent	bear, carry

G

galact-	milk
gastr-	stomach
-genesis	origination, production
glome-	ball
glosso-	tongue
glyc-	sweet
-gnosis	knowledge
gusta-	to taste
gyn-	woman
gyr-	ring, circle

H

hem-	blood
heml-	half
hepat-	liver
hetero-	varied, unlike, different
homeo-	alike
homo-	same
hydro-	water
hyper-	above; excess
hypo-	below, deficient
hystero-	uterus

I

in-	into, not
infra-	below, under
insul-	island
inter-	between
intra-	within
iso-	equal, like
-itis	inflammation

J

juxta-	next to
--------	---------

K

kerat-	horn
--------	------

L

labl-	lip
leuk-	white
lip-	fat
-lysis	dissolving, destruction, separation

M

macro-	large
mal-	bad
mega-	large, great
megalo-	
melan-	black
mening-	membrane
mens-	month
meso-	middle
mono-	one, single
morpho-	shape, form
myo-	muscle

N

necro-	dead
nephro-	kidney
neuro-	nerve

O

-oid	resembling
-ole	small
olfact-	to smell
oligo-	scant, sparse
-oma	tumor, swelling
ophthalmo-	eye
-opia	vision
-osis	a condition, a process
oss-, ost-	bone
ot-, oto-	ear
ov-	egg

P

para-	beside, near, beyond
patho-	disease
peri-	around
pes-, ped-	foot
phago-	eat
phlebo-	vein
-pnea	breathing
pneum-	air
poly-	many
post-	behind, after
pre-	before, in front of
pro-	before, giving rise to
psycho-	mind
pulmo-	lung

R

reti-	network
retro-	backward, behind
rhin-	nose
-rrhea	flow

S

sarc-	flesh
scler-	hard
semi-	half
sept-	fence, wall off
soma-	body
sperma-	seed
sub-	below
super-	above, upon, excessive
supra-	above, upon
syn-	with, together

T

tachy-	swift
thrombo-	clot, lump
trans-	across
tri-	three
-trophe	nourishment

U

-ule	small
ultra-	(beyond, excess
uni-	one

V

vas-, vaso-	vessel
-------------	--------

INDEX OF CONTENTS

	Page
(1) Descriptive anatomical terms _____	1-3
(2) Skin _____	4-6
(3) Fascia _____	7-8
(4) Tendons _____	9
(5) Cartilage _____	10-11
(6) Bone _____	12-18
(7) Joints _____	19-24
(8) Muscles _____	25-30
(9) Blood circulation _____	31
(10) Blood vessels _____	32-35
(11) Lymphatic system _____	36-37
(12) Serous membranes _____	38
(13) Nervous system _____	39-46
(14) Glossary _____	47-59